*Ahead of print*

*Med Ultrason 2026:0, 1-6 Online first*
**DOI:** 10.11152/mu-4649

# Feasibility and early clinical outcomes of ultrasound-guided coccygeal nerve pulsed radiofrequency in refractory post-traumatic coccygodynia

**Sefa Tan, Banu Gokcen Tan, Ruhiye Reisli, Sema Tuncer Uzun**

Pain Medicine Department, Necmettin Erbakan University, Konya, Türkiye

**Abstract**

**Aims:** To evaluate the feasibility, safety, early clinical outcomes of a staged ultrasound-guided coccygeal nerve intervention algorithm incorporating pulsed radiofrequency (PRF) in refractory post-traumatic coccydynia. **Material and methods**: Twelve patients underwent a two-phase routine clinical protocol: ultrasound-guided bilateral coccygeal nerve block followed, if pain persisted at three weeks, by PRF combined with a repeat nerve block. Outcomes included Numeric Rating Scale-sitting (NRS-sitting), sitting tolerance, and Patient Global Impression of Change (PGIC) over 8 weeks. **Results:** Feasibility endpoints were met with no complications. NRS-sitting decreased from 6.33±1.23 to 2.17±0.72 at week 8 (95% CI: 1.71–2.63; $p<0.001$). At week 8, 58.3% of patients could sit for >30 minutes, and 75% reported high satisfaction (PGIC scores of 6 or 7). Findings should be interpreted as preliminary feasibility and short-term clinical outcomes of the staged intervention algorithm. **Conclusion**: These preliminary findings suggest that a staged ultrasound-guided approach incorporating PRF is feasible and safe for refractory coccydynia, with short-term improvements in pain and functional sitting tolerance reflecting the overall staged protocol rather than the isolated effect of PRF. Larger randomized controlled trials with longer follow-up are required to determine clinical efficacy, long-term durability, and the incremental contribution of PRF.

**Keywords:** Ultrasound-guided intervention; coccygeal nerve; pulsed radiofrequency

## Introduction

Coccygodynia refers to localized pain in the coccyx region, often resulting from trauma and significantly affecting mobility [1]. Post-traumatic cases are often refractory to conventional treatments such as physical therapy or pharmacological agents [2]. In such refractory cases, interventional procedures such as caudal epidural injections, ganglion impar blocks, and coccygeal nerve blocks have been reported to be effective treatment options [3]. Interest in ultrasound-guided coccygeal nerve interventions has grown in recent years due to their superficial anatomical landmarks, ease of sonographic visualization, and the advantage of avoiding radiation exposure [4-6]. These studies suggest that direct targeting of the coccygeal nerves may represent a more anatomically focused peripheral approach than ganglion impar–based interventions. Despite these promising developments, the current literature remains limited, and the potential role of neuromodulatory techniques has not been explored. Pulsed radiofrequency (PRF) provides a non-neurodestructive neuromodulation modality that has shown favorable outcomes in a variety of chronic pain syndromes [7].

Unlike centrally oriented ganglion impar–based interventions, this study explores a peripheral neuromodulatory strategy targeting the distal coccygeal nerve plane under ultrasound guidance. To our knowledge, the app-

Received 12.04.2026 Accepted 26.07.2026
Early Access publication date 11.09.2026
Med Ultrason
2026:0 Online first, 1-6
Corresponding author: Sefa Tan, MD
Pain Medicine Department,
Necmettin Erbakan University,
42040 Konya, Türkiye
E-mail: sefatan@yahoo.com
Phone: +90 506 894 95 44

lication of ultrasound-guided PRF specifically targeting the coccygeal nerves has not been previously reported in a structured cohort. In this context, we evaluated the short-term clinical outcomes of a staged ultrasound-guided coccygeal nerve intervention algorithm in patients with refractory post-traumatic coccygodynia. This pilot study aims to provide preliminary feasibility and outcome data to inform future larger-scale randomized controlled trials.

## Materials and methods

### *Study design and ethical approval*

This observational pilot feasibility study evaluated consecutive patients treated at a tertiary pain clinic between 01.01.2025 and 01.02.2026. The staged ultrasound-guided coccygeal nerve block/PRF algorithm was applied as part of routine clinical practice, and ethics committee approval was subsequently obtained for the evaluation and reporting of the clinical outcomes of this cohort (Decision No: 2026/6377, approval date: 27 February 2026). After ethics committee approval, the routinely recorded clinical and follow-up data were reviewed and analyzed for research purposes. The study was performed in accordance with the principles of the Declaration of Helsinki. Written informed consent for the clinical procedures was obtained from all patients prior to the interventions.

### *Participants*

A total of 12 patients (7 females, 5 males) with chronic post-traumatic coccygodynia refractory to conservative treatment for at least 3 months were included. The sample size was determined according to the rule-of-thumb approach for pilot studies proposed by Julious, suggesting that approximately 10–12 participants are sufficient to estimate variability and inform future sample size calculations. Inclusion criteria were: age >18 years, diagnosis of post-traumatic coccygodynia, and Numeric Rating Scale (NRS) score ≥5 during sitting. Exclusion criteria included local infection, malignancy, and previous coccygeal surgery. The patient selection process and study workflow are summarized in figure 1.

### *Feasibility endpoints*

The predefined feasibility endpoints of this pilot study were the technical success of the ultrasound-guided bilateral intervention, adequate visualization of the target anatomical landmarks, completion of follow-up assessments, and the absence of major procedure-related complications.

### *Procedures*

All procedures were performed with patients in the prone position under strict sterile conditions. The sacral

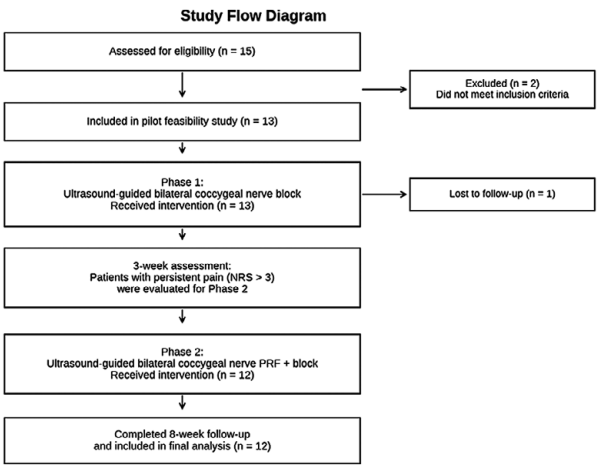


**Fig 1.** Study flow diagram.

cornua were initially identified in the transverse plane using a 5–12 MHz linear transducer (Esaote, MyLab Six, Genoa, Italy). The transducer was then advanced caudally to visualize the superficial hyperechoic contours of the coccygeal cornua.

Phase 1 (Diagnostic Coccygeal Nerve Block): Under real-time ultrasound guidance, the needle was advanced from lateral to medial at an angle of approximately 30–40° using an in-plane approach toward the target plane located superomedial to the coccygeal cornua (fig 2a). Following negative aspiration, 2 mL of 2% lidocaine was injected (fig 2b). The same procedure was subsequently performed on the contralateral side. No immediate or delayed complications were observed.

Phase 2 (PRF combined with repeat coccygeal nerve block): Phase 1 served as a diagnostic ultrasound-guided coccygeal nerve block. Pain response was assessed at 1 hour, and all patients included in the final analysis were re-evaluated at the 3-week follow-up before undergoing Phase 2, which consisted of ultrasound-guided bilateral PRF combined with repeat coccygeal nerve block. Patients were subsequently re-evaluated at 8 weeks for pain intensity, sitting tolerance, and treatment success.

For the PRF procedure, a 22-gauge, 6-cm radiofrequency cannula with a 5-mm active tip was advanced toward the target using the same ultrasound-guided technique. Sensory stimulation at 0.4–0.7 V (50 Hz) elicited paresthesia in the coccygeal and rectal regions, while the absence of motor response at 2 V (2 Hz) confirmed appropriate and safe needle placement. PRF was applied bilaterally at 42°C for 6 minutes, followed by an injectate consisting of 2 mL of 2% lidocaine and 4 mg dexamethasone. No procedure-related complications were recorded.

### *Statistical analysis*

Statistical analyses were performed using SPSS version 27 (IBM Corp., Armonk, NY, USA). Continuous

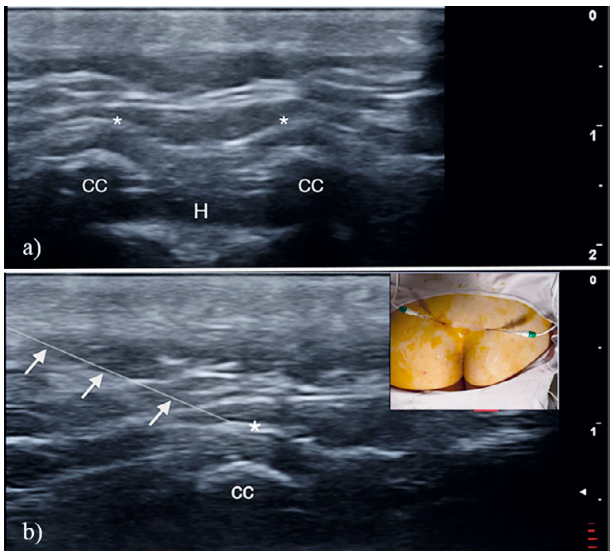


**Fig 2.** a) Sonographic anatomy of the coccygeal region in the transverse plane. The coccygeal cornua (CC) are visualized as hyperechoic bony structures with posterior acoustic shadowing. H indicates the hiatus, and asterisks (*) indicate the coccygeal nerves; b) Ultrasound-guided coccygeal nerve block and PRF technique. The needle is advanced using an in-plane approach, targeting the superomedial region of the coccygeal cornua (CC), indicated by the asterisk (*). The arrows indicate the direction of needle advancement. The inset at the top right shows the bilateral orientation of the needle during PRF application to the coccygeal nerve in the prone position.

variables were presented as mean ± standard deviation (SD), and categorical variables as number (percentage). Given the small sample size and the ordinal nature of several outcome measures, nonparametric tests were used. Changes in NRS-sitting scores across repeated assessments (baseline, 1 hour, 3 weeks, and 8 weeks) were analyzed using the Friedman test. When the overall comparison was significant, post-hoc pairwise comparisons were performed using the Wilcoxon signed-rank test with Bonferroni-adjusted p values. Sitting tolerance, recorded as ordinal categories (<10 min, 10–30 min, >30 min), was also analyzed across time points using the Friedman test. PGIC scores at week 3 and week 8 were summarized descriptively as frequency distributions. Approximate 95% confidence intervals were calculated for mean NRS-sitting scores at each time point and for the proportion of patients with PGIC scores of 6 or 7 at week 8. All tests were two-tailed, and a p value < 0.05 was considered statistically significant. Given the exploratory nature of this pilot study and the limited sample size, all analyses were considered hypothesis-generating, and the descriptive clinical findings were emphasized in the interpretation.

***Outcome measures***

Pain intensity during sitting was assessed using the NRS during sitting (NRS-sitting), where patients rated their average pain intensity while sitting on an 11-point scale ranging from 0 (no pain) to 10 (worst imaginable pain).

Sitting tolerance was evaluated by asking patients to report the maximum duration they were able to sit without requiring position change or standing due to pain. Sitting tolerance was recorded using predefined duration categories (<10 min, 10–30 min, >30 min).

Global treatment effectiveness was assessed using the Patient Global Impression of Change (PGIC) scale. Patients rated their overall perceived change in pain and functional status following the intervention on a 7-point Likert scale, ranging from "very much worse" to "very much improved."

Outcome measures were recorded at baseline and at predefined follow-up visits.

## Results

***Study population and feasibility***

A total of 12 patients (mean age 42.6 ± 9.9 years; 58.3% female) with refractory post-traumatic coccygodynia were included. The baseline demographic and clinical characteristics of the study population are summarized in Table I. The mean duration of symptoms prior to intervention was 4.6 months. Feasibility endpoints were achieved in all 12 patients included in the final analysis: target anatomical landmarks were adequately visualized under ultrasound guidance, all planned bilateral interventions were completed without technical failure, follow-up was completed, and no major procedure-related complications were observed.

***Pain intensity (NRS-sitting)***

Mean NRS-sitting scores showed a reduction over time in this exploratory analysis (Friedman test, p<0.001).

Table I. Baseline characteristics of the study population (n = 12).

| Variable | Value |
|---|---|
| Age (years), mean ± SD | 42.6±9.9 |
| Sex, n (%) | |
| Male | 5 (41.7%) |
| Female | 7 (58.3%) |
| Duration of symptoms (months), mean (range) | 4.6 (3-10) |
| Baseline NRS-sitting, mean ± SD | 6.33±1.23 |
| Sitting tolerance, n (%) | |
| <10 min | 6 (50.0%) |
| 10-30 min | 6 (50.0%) |
| >30 min | 0 (0%) |

Values are presented as mean±standard deviation, mean (range), or number (percentage), as appropriate. NRS: Numeric Rating Scale.

The mean baseline NRS score was 6.33±1.23 (95% CI: 5.55–7.11), which decreased to 1.83±0.83 (95% CI: 1.30–2.36) at 1 hour post-procedure. At 3 weeks, a partial increase was observed with a mean score of 3.58±0.79 (95% CI: 3.08–4.09), followed by a further reduction to 2.17±0.72 (95% CI: 1.71–2.63) at 8 weeks (fig 3). Pairwise comparisons performed with Bonferroni correction showed significant reductions between baseline and all follow-up time points. In addition, the reduction from week 3 to week 8 remained significant after post-hoc correction.

***Functional improvement (sitting tolerance)***

Sitting tolerance improved substantially over time. At baseline, 50% of patients were unable to sit for more than 10 minutes, and none were able to sit for longer than 30 minutes. By week 3, the majority of patients (91.7%) were able to tolerate sitting for 10–30 minutes. At week 8, 58.3% of patients were able to sit for more than 30 minutes, and no patients remained in the <10-minute category, indicating a marked functional improvement (fig 4).

***Patient satisfaction and safety***

At week 3, most patients reported either minimal or moderate improvement, with 66.7% rated as "minimally improved" (PGIC = 5) and 33.3% as "much improved" (PGIC = 6). No patient was rated as "very much improved" (PGIC = 7) at this time point. By week 8, patient-reported outcomes shifted toward greater improvement: 33.3% were rated as "very much improved," 41.7% as "much improved," and 25.0% as "minimally improved." Overall, 75.0% of patients reported a PGIC score of 6 or 7 at the final follow-up, indicating high patient satisfaction (95% CI: 46.8%–91.1%). No major procedure-related complications, including hematoma, infection, rectal injury, or persistent neurological deficits, were observed.

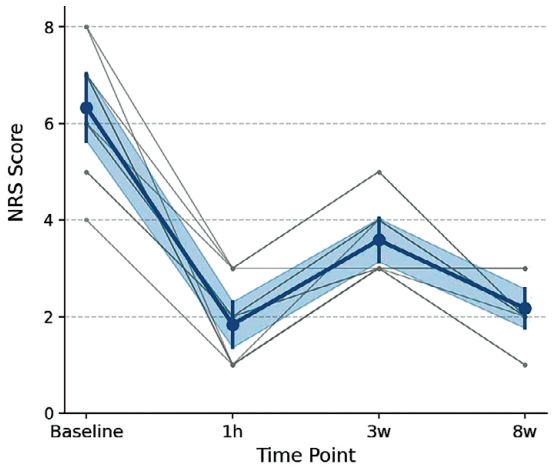


**Fig 3.** Individual patient trajectories of NRS-sitting scores over time, together with the group mean and 95% confidence interval. Gray lines represent individual patients, the blue line represents the group mean, and the shaded area represents the 95% confidence interval of the mean.

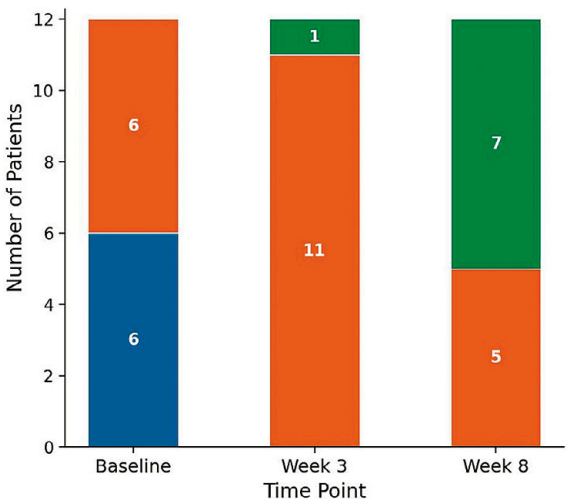


**Fig 4.** The distribution of sitting tolerance categories at baseline, week 3, and week 8. Sitting tolerance categories were defined as Category 1 = <10 minutes, Category 2 = 10–30 minutes, and Category 3 = >30 minutes; colors represent these categories as blue = 1, orange = 2, and green = 3. Numbers inside the bars indicate patient counts.

## Discussion

This pilot study highlights the potential clinical value of an ultrasound-guided coccygeal nerve–targeted interventional strategy in the treatment of refractory post-traumatic coccygodynia. While conservative treatments such as nonsteroidal anti-inflammatory drugs, sitting aids, and manual manipulation remain the first-line approach, a significant portion of patients fail to achieve satisfactory relief [8]. In recent years, image-guided interventional techniques and neuromodulation methods have gained prominence, as they allow more precise targeting of pain-generating structures [9]. While there is no definitive consensus on the optimal injection site for coccygodynia, the use of imaging guidance is highly recommended to increase accuracy and safety [10].

Ultrasound-guided coccygeal nerve block has emerged as a relatively novel interventional approach in the management of coccygodynia [4]. In recent years, the number of studies reporting successful analgesic efficacy with coccygeal nerve block has increased. One study evaluating the effectiveness of coccygeal nerve block showed that it was as effective as ganglion impar block in selected patients with coccygodynia [6]. The absence of radiation exposure due to its ultrasound-guided application, the superficial course of the coccygeal nerves, and the low needle penetration depth make it easier to ap-

ply. Taken together, these findings support the coccygeal nerve plane as a clinically meaningful peripheral target for intervention. These features may support its use as an attractive alternative in selected patients with coccygodynia.

PRF is an interventional neuromodulation method increasingly preferred in the treatment of chronic neuropathic pain [7]. It has been shown to modulate numerous pathways involved in pain transmission, such as nociceptive signaling, immune response, and synaptic activity at the cellular and molecular level [11, 12]. This mechanism distinguishes PRF from conventional neuroablative techniques and supports its use as a neuromodulatory rather than destructive intervention. Numerous clinical studies supporting its analgesic efficacy in various peripheral and axial pain syndromes confirm these data [13-15]. Therefore, PRF has been proposed as an alternative to classical neuroablative methods because of its non-destructive neuromodulatory profile and favorable safety characteristics.

To our knowledge, this pilot study represents one of the first clinical investigations evaluating PRF applied directly to the coccygeal nerves. Importantly, the novelty of the present study lies not merely in targeting the coccygeal nerves, but in evaluating a staged, ultrasound-guided, peripheral PRF-based treatment algorithm in patients with refractory post-traumatic coccygodynia. Based on its favorable safety profile and low risk of adverse effects, PRF was administered following diagnostic coccygeal nerve blockade in patients with persistent pain. The maintenance of analgesic improvement at the 8-week follow-up supports the potential clinical value of a stepwise treatment algorithm including PRF, consistent with the direction of benefit reported for PRF in other peripheral pain conditions [16,17]. Previous studies have shown that combined coccygeal nerve block and radiofrequency ablation (RFA) can significantly improve pain and functional outcomes at short- and mid-term follow-up intervals [5]. Thus, our findings are broadly aligned with the direction of benefit reported in prior coccygeal nerve intervention studies, while extending the literature toward a non-neurodestructive PRF-based strategy. However, because Phase 2 combined PRF with repeat coccygeal nerve block using lidocaine and dexamethasone, the independent contribution of PRF cannot be isolated. Therefore, the observed improvement should be interpreted as reflecting the overall staged intervention strategy rather than the isolated effect of PRF alone.

Other interventional techniques, such as caudal epidural steroid injection and ganglion impar block, are also commonly employed in the treatment of coccygodynia. However, these procedures are typically performed under fluoroscopic guidance, which involves ionizing radiation exposure and carries risks such as rectal perforation, cauda equina injury, and discitis. In contrast, ultrasound-guided coccygeal nerve interventions allow direct visualization of relevant anatomical landmarks, a controlled and superficial needle trajectory, and a greater distance from the epidural space, thereby potentially reducing procedure-related complications. The complete elimination of radiation exposure represents an additional safety advantage for both patients and clinicians, particularly when repeated interventions are required. Although these theoretical and practical advantages do not establish superiority over existing comparator interventions, they provide a strong rationale for further controlled comparative studies.

An additional strength of the present study is that the observed reduction in pain was accompanied by functional improvement, particularly in sitting tolerance, which is the most clinically relevant disability domain in coccygodynia. The favorable PGIC responses further suggest that the observed changes were meaningful from the patient perspective and not limited to pain score reduction alone.

This study has several limitations. First, the sample size was small and the study was conducted at a single center, which limits statistical precision and generalizability. Second, the absence of a control group and randomization precludes firm conclusions regarding causality. Because the study was based on clinical follow-up data, outcome assessment was limited to measures available in routine practice, and potential confounders such as analgesic use, psychosocial factors, and occupational sitting exposure could not be fully controlled. Third, the follow-up period was relatively short at 8 weeks; this is short for a chronic pain condition, and the long-term durability of the observed benefits beyond this window remains entirely unknown. In addition, Phase 2 included not only pulsed radiofrequency (PRF) but also repeat coccygeal nerve block with lidocaine and dexamethasone. Therefore, the relative contribution of PRF versus the analgesic and anti-inflammatory effects of the concomitant injectate cannot be clearly distinguished. The 8-week outcomes should thus be interpreted as reflecting the overall staged interventional strategy rather than the isolated effect of PRF alone. Finally, only patients with post-traumatic coccygodynia were included, which may limit the applicability of the findings to other etiologies. These limitations highlight the need for larger, randomized controlled trials with longer follow-up to confirm the present preliminary findings. The optimal future design would be a three-arm randomized controlled trial comparing conservative treatment or sham control,

coccygeal nerve block alone, and coccygeal nerve block combined with PRF, with longer follow-up, which would allow the incremental contribution of PRF to be isolated.

## Conclusion

In conclusion, to our knowledge, this pilot feasibility study is among the first reports suggesting that a staged ultrasound-guided algorithm incorporating coccygeal nerve PRF may be feasible and clinically relevant for refractory post-traumatic coccygodynia. These findings should be interpreted as preliminary short-term clinical outcome data related to the overall staged intervention strategy rather than evidence of an isolated PRF effect. Further randomized controlled trials, including a comparator arm with nerve block alone, are required to better define optimal treatment protocols, the incremental contribution of PRF, and long-term outcomes.

**Conflict of interest**: none

## References

1. Bain HL, Mabrouk A, Foye P. Coccyx pain. In: StatPearls [Internet]. Treasure Island (FL): StatPearls Publishing; 2025.
2. Garg B, Ahuja K. Coccydynia: a comprehensive review on etiology, radiological features, and management options. J Clin Orthop Trauma 2021;12:123-129.
3. Lee SH, Yang M, Won HS, et al. Coccydynia: anatomic origin and considerations regarding the effectiveness of injections for pain management. Korean J Pain 2023;36:272-280.
4. Wu WT, Hsu YC, Chang KV, et al. Ultrasound imaging and ultrasound-guided injection of the coccygeal nerve for coccydynia. Am J Phys Med Rehabil 2022;101:e108-109.
5. Can E, Yildiz G, Akkaya OT, et al. Ultrasound-guided coccygeal nerve radiofrequency ablation and steroid injection: combination therapy for coccydynia. J Ultrasound Med 2024;43:57-64.
6. Genc Perdecioglu GR, Yildiz G. Coccygeal Nerve Blockade vs. Impar Ganglion Blockade in Coccydynia: A Randomised Clinical Trial. Cureus 2024;16:e69118.
7. Chua NH, Vissers KC, Sluijter ME. Pulsed radiofrequency treatment in interventional pain management: mechanisms and potential indications. Acta Neurochir (Wien) 2011;153:763-771.
8. Elkhashab Y, Ng A. A review of current treatment options for coccygodynia. Curr Pain Headache Rep 2018;22:28.
9. Deng A, Patel M, Eigner C, et al. General innovations in pain management. J Clin Med 2025;14:5957.
10. Lirette LS, Chaiban G, Tolba R, et al. Coccydynia: an overview of the anatomy, etiology, and treatment of coccyx pain. Ochsner J 2014;14:84-87.
11. Jordan S, Catapano M, Sahni S, et al. Pulsed radiofrequency in interventional pain management: cellular and molecular mechanisms of action. Pain Physician 2021;24:525-532.
12. Park D, Chang MC. The mechanism of action of pulsed radiofrequency in reducing pain: a narrative review. Yeungnam Univ J Med. 2022;39:200-205.
13. Boudier-Revéret M, Thu AC, Hsiao MY, et al. Effectiveness of pulsed radiofrequency on joint pain: a narrative review. Pain Pract 2020;20:412-421.
14. Chang MC. Efficacy of pulsed radiofrequency stimulation in patients with peripheral neuropathic pain: a narrative review. Pain Physician 2018;21:E225-234.
15. Yang S, Boudier-Revéret M, Chang MC. Use of pulsed radiofrequency for the treatment of discogenic back pain: a narrative review. Pain Pract 2021;21:594-601.
16. Tanyel Saracoglu T, Bilir A, Gulec MS. Effectiveness of combining greater occipital nerve block and pulsed radiofrequency treatment in patients with chronic migraine: a double-blind randomized controlled trial. Head Face Med 2024;20:48.
17. Wu Y, Huang J, Zhang W, et al. Comparison of combined suprascapular and axillary nerve pulsed radiofrequency and nerve block for the treatment of primary frozen shoulder. Ann Med. 2025;57:2456692.