Original papers

Med Ultrason 2025, Vol. 27, no. 3, 261-267
DOI: 10.11152/mu-4491

Ultrasound Attenuation, Liver Texture Index, and HepatoRenal Index: Assessing Reproducibility and Inter-operator Consistency in Clinical Practice

Fan Liu[1,2], Haiyan Zeng[2], Xingxing Yuan[2], Lingyue Du[2], Xiaoting Wu[2], Xue Han[2], Zaiqiang Chen[3], Shuai Yang[4], Jian Zheng[1,2]

[1]The First School of Clinical Medicine, Guangdong Medical University, Zhanjiang, [2]Ultrasound Department of The Second Affiliated Hospital, School of Medicine, The Chinese University of Hong Kong, Shenzhen and Longgang District People's Hospital of Shenzhen, Shenzhen, [3]Health Education Department of The Second Affiliated Hospital, School of Medicine, The Chinese University of Hong Kong, Shenzhen and Longgang District People's Hospital of Shenzhen, Shenzhen,[4] Department of Clinical and Research, Shenzhen Mindray Bio-medical Electronics Co., Ltd., Shenzhen, China

Abstract

Aim: This study aimed to evaluate the reproducibility of Ultrasound Attenuation (USAT), the Liver Texture Index (LTI) and the HepatoRenal Index (HRI). **Material and methods:** Between May 2023 to December 2023, 279 patients who underwent USAT, LTI and HRI tests at the Ultrasound Department of The Second Affiliated Hospital, School of Medicine, The Chinese University of Hong Kong, Shenzhen were included. All patients were examined by a physician with over 4 years of ultrasound experience. The intra-class correlation coefficient (ICC) was utilized to assess the reproducibility of the three quantitative parameters in all patients. Additionally, 63 cases were examined by another physician with six months of experience to evaluate inter-operator reproducibility. **Results:** The intra-operator reproducibility of USAT, LTI, and HRI were 0.879 (95% CI:0.858-0.898), 0.919 (95% CI:0.904-0.933), and 0.836 (95% CI:0.809-0.862), respectively. The inter-operator reproducibility among different operators were 0.790 (95% CI:0.604-0.894), 0.782 (95% CI:0.591-0.890), and 0.631 (95% CI:0.356-0.806). After 30 operations, the inter-operator reproducibility improved to 0.858 (95% CI:0.731-0.927), 0.909 (95% CI:0.823-0.954), and 0.796 (95% CI:0.587-0.899). **Conclusions:** USAT, LTI, and HRI have shown good intra-operator reproducibility, and inter-operator reproducibility between the two operators reached a comparable level after 30 training cases.

Keywords: UltraSound Attention (USAT); Liver Texture Index (LTI); HepatoRenal Index (HRI); Hepatic Steatosis; Reproducibility

Introduction

With changes in dietary habits and lifestyles, fatty liver disease has emerged as the predominant chronic liver condition in China, with a rising prevalence [1-3]. Liver biopsy remains the current gold standard for assessing hepatic steatosis severity [4]. However, its clinical utility is constrained by invasiveness, poor reproducibility, and potential complications [5-6]. B-mode ultrasound, being convenient, noninvasive, and cost-effective, is widely used for hepatic steatosis diagnosis [7-9], the sensitivity was 84.8% for the detection of moderate-severe fatty liver [10]. Nevertheless, the inherent subjectivity of conventional ultrasound imaging underscores an imperative clinical requirement for a precise, quantitative diagnostic modality capable of reliably grading and diagnosing hepatic steatosis [11].

The Multi-parametric Fatty Liver Lab, incorporating Ultrasound Attenuation (USAT), Liver Texture Index (LTI), and HepatoRenal Index (HRI), represents a novel

Received 08.10.2024 Accepted 19.01.2025
Med Ultrason
2025, Vol. 27, No 3, 261-267
Corresponding author: Jian Zheng
The First School of Clinical Medicine,
Guangdong Medical University,
Zhanjiang 524000, China;
Ultrasound Department of The Second
Affiliated Hospital, School of Medicine,
The Chinese University of Hong Kong,
Shenzhen & Longgang District People's
Hospital of Shenzhen,
Shenzhen, 518172, China
E-mail: zhengjian@cuhk.edu.cn

non-invasive quantitative approach to assessing hepatic steatosis, offering diverse quantitative parameters. Despite its potential, this technique remains underutilized in clinical settings, with limited literature on its reproducibility.

Thus, this study seeks to investigate the intra- and inter-operator reproducibility of three quantitative parameters-USAT, LTI, and HRI, to evaluate hepatic steatosis severity. The aim is to establish an evidence-based foundation for the clinical implementation of this novel technology.

Materials and methods

Subjects

The study was approved by the Ethics Committee of Ultrasound Department of The Second Affiliated Hospital, School of Medicine, The Chinese University of Hong Kong, Shenzhen (approval ID: 2024004). Written informed consent was obtained from the patients according to the National Health and Medical Research Council guidelines. We prospectively enrolled patients at risk of hepatic steatosis who underwent ultrasound examinations at the Ultrasound Department of The Second Affiliated Hospital, School of Medicine, The Chinese University of Hong Kong, Shenzhen, from May 2023 to December 2023. Inclusion criteria included: 1. Age ≥18 years; 2. Preliminary diagnosis of fatty liver disease by 2D ultrasound; 3. Consent to undergo USAT, LTI, and HRI quantitative parameter testing, and signed an informed consent form. Exclusion criteria were: 1. Inability to cooperate with the examination due to respiratory difficulties or other reasons; 2. History of heavy alcohol consumption (more than 21 drinks per week for men and more than 14 drinks per week for women); 3. History of liver surgery; 4. History of liver space-occupying lesions; 5. History of compensated or decompensated liver disease; 6. Other chronic liver diseases (such as drug-induced liver disease, viral or autoimmune hepatitis, etc.); 7. History of kidney diseases (such as renal tumors, polycystic kidney disease, acute or chronic nephritis, nephrotic syndrome, etc.); 8. Chronic heart failure; 9. Pregnancy; 10. Other severe comorbidities (fig 1).

Study design

All patients were examined by an ultrasound physician (H.Y.Z.) with over 4 years of ultrasound experience. The operators were trained in the basic operational techniques of USAT, LTI, and HRI quantitative parameter testing, familiarized with the instrumental procedures, and then conducted the tests independently. To assess the intra-operator reproducibility of the three techniques, each was independently repeated five times. Among these patients, 63 cases were also examined by another ultrasound physician (F.L.) who had only six months of ultrasound experience and had undergone training. Both operators performed their measurements independently and were blinded to the results of each other to ensure the objectivity of the assessments. Each technique was repeated five times, and the median values were taken. The medians from the two operators were compared to evaluate the inter-operator reproducibility. The time interval between examinations by the two operators was less than one hour.

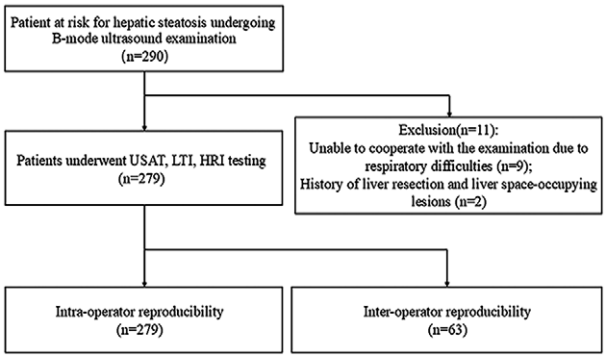

Fig 1. Flow chart of the study population

Ultrasound examination

Each scan was conducted using a Resona 9 ultrasound system (Mindray, China) with an SC6-1U convex array probe operating at a frequency of 1-6 MHz. Our operational approach is in strict accordance with the most recent WFUMB Guidelines [12]. Patients were required to fast for at least 6 hours before the examination. They were positioned in the supine position for USAT and LTI measurements, and in the left decubitus position for HRI measurements, with the right arm raised to expose the right quadrate ribs. All subjects were assessed for the three quantitative parameters. The test involved holding the breath for 3-5 seconds in a calm respiratory state. The test was repeated five times, and the median value was recorded.

Ultrasound Attenuation (USAT): The right hepatic parenchyma was selected to avoid rib shadows, with the region of interest (ROI) avoiding large blood vessels where possible. The upper edge of the ROI was positioned approximately 1-2 cm away from the hepatic capsule, as close to the center of the image as feasible. The probe was perpendicular to the hepatic capsule, and the patient was instructed to hold their breath in a calm respiratory state. The image was then stabilized, frozen, and measurements were taken (fig 2a).

Liver Texture Index (LTI): The right liver parenchyma was chosen to avoid rib shadows, with the ROI positioned to avoid large blood vessels. The ROI was placed

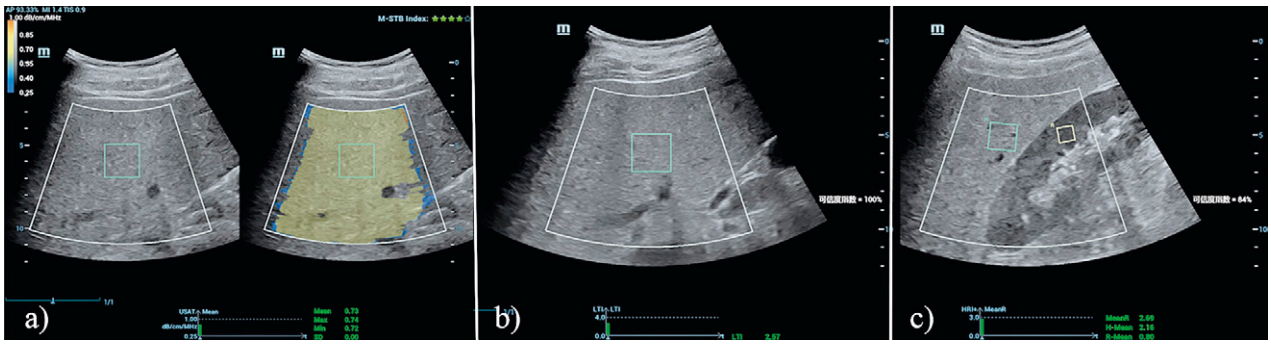

Fig 2. Measured images of ultrasound attention, liver texture index, and hepatorenal index in the same patient with fatty liver disease: a) ultrasound attention; b) liver texture inde; c) hepatorenal index

as close to the center of the image as possible. The probe was perpendicular to the hepatic capsule, and the patient was instructed to hold their breath in a calm respiratory state. The image was frozen and measurements were taken once the image had stabilized (fig 2b).

HepatoRenal Index (HRI): A longitudinal section of the liver and right kidney was selected to avoid rib shadows, with the ROI avoiding large blood vessels as much as possible. A large green box was placed in the liver parenchyma, and a small yellow box in the renal cortex. The patient was instructed to hold their breath in a calm respiratory state. The image was then frozen and measurements were taken after stabilization (fig 2c).

Image quality standard

Two operators performed five measurements of each of the three techniques, with the requirement that the IQR/median ratio of the measured values for each technique be less than 0.30. Furthermore, we utilized the Motion Stability Index (M-STB Index) and the Reliability Map (RLB MAP) configured on the machine to assess the reliability and stability of the measurements. The M-STB Index evaluates the motion stability of the images during the examination and enables real-time monitoring of whether patients are effectively cooperating with the breathing instructions. For good image stability, it is necessary to display at least four stars and a green indication. The RLB MAP can be displayed synchronously with the examination images, guiding physicians in the quality control of the imaging, with a requirement of over 80% to indicate high credibility.

Statistical analysis

SPSS 27.0 and MedCalc 19.8 statistical software were applied for data analysis. Measurements were presented as mean ± standard deviation ($\bar{x} \pm s$) and analyzed using the *T* test. The reproducibility of the assay was evaluated by the intraclass correlation coefficient (ICC), and ICC ≥ 0.75 indicating good agreement. All ICC comparisons were conducted using the *Z* test. Statistical significance was considered at $P < 0.05$.

Results

A total of 290 patients were enrolled in the study. After excluding 9 patients who could not cooperate due to respiratory issues and 2 patients with a history of liver resection and liver space-occupying lesions, 279 patients remained and participated in this study. All 279 patients underwent ultrasound assessments with USAT, LTI, and HRI, consisting of 55 males and 224 females. The demographic characteristics of the participants are detailed in Table I.

Intra-operator reproducibility

The intra-operator reproducibility of the three quantitative parameters of USAT, LTI, and HRI testing is shown in Table II. The reproducibility of all five measurements for each parameter demonstrated high consistency (ICC: 0.836-0.919). Further analysis focusing on the first three measurements revealed an ICC range of 0.860-0.930. Notably, the difference in ICC values between the five measurements and the three measurements was statistically insignificant (p>0.05).

Inter-operator reproducibility

Reproducibility analyses of the three quantitative parameters of USAT, LTI, and HRI testing by the two operators in 63 patients are shown in Table III. Initially, for the first 30 patients, the inter-operator reproducibility between the operators was moderate (ICC: 0.631-0.790). A Bland-Altman scatter plot illustrating the inter-operator agreement is depicted in fig 3. Following 30 training sessions, the inter-operator repeatability improved significantly (ICC: 0.796-0.909), with the corresponding Bland-Altman scatter plot displayed in fig 4.

Table I. The demographic characteristics of the patients

Characteristics	Patients (n=279)
Age, years (SD; range)	37.1(8.2; 20-62)
Gender, male (%)	55(19.7%)
BMI, kg/m^2 (SD; range)	27.7(3.9;20.7-53.9)

SD = standard deviation; BMI=body mass index

Confidence and variability of the tests

Table IV outlines the confidence and variability of the quantitative parameters of USAT, LTI, and HRI between the two operators. Both novice (operator A) and experienced (operator B) operators exhibited a confidence level exceeding 80% and variability below 30%. However, a statistically significant difference was observed between the operators in terms of the reliability and variability of the USAT assay and the reliability of the HRI measurement ($p<0.05$).

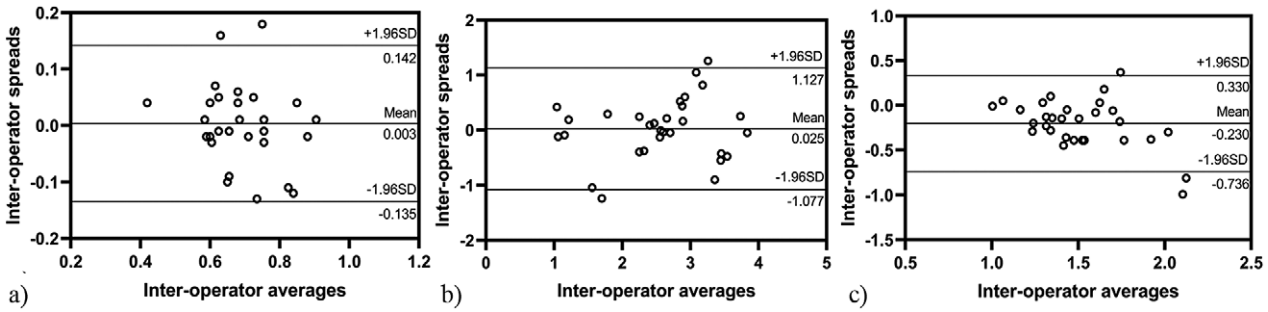

Fig 3. Bland-Altman scatterplot of inter-operator agreement between the first 30 cases: a) USAT; b) LTI; c: HRI

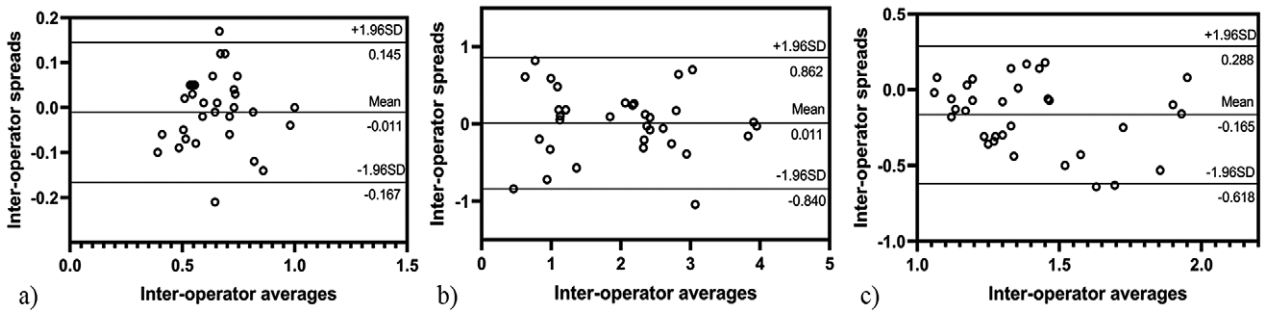

Fig 4. Bland-Altman scatterplot of inter-operator agreement after 30 cases: a) USAT; b) LTI; c) HRI

Table II. Intra-operator reproducibility of USAT, LTI, and HRI

	Testing 5 times (ICC, 95% CI)	**Testing 3 times (ICC, 95% CI)**	**Z**	**p**
USAT	0.879 (0.858, 0.898)	0.860 (0.832, 0.884)	0.916	0.360
LTI	0.919 (0.904, 0.933)	0.930 (0.915, 0.942)	0.891	0.373
HRI	0.836 (0.809, 0.862)	0.867 (0.840, 0.890)	1.329	0.184

CI = confidence interval

Table III. Inter-operator reproducibility of USAT, LTI, and HRI

	30 cases before operation (ICC, 95% CI)	**after 30 cases of operation (ICC, 95% CI)**	**Z**	**p**
USAT	0.790 (0.604, 0.894)	0.858 (0.731, 0.927)	0.808	0.419
LTI	0.782 (0.591, 0.890)	0.909 (0.823, 0.954)	1.776	0.076
HRI	0.631 (0.356, 0.806)	0.796 (0.587, 0.899)	1.299	0.194

CI = confidence interval

Table IV. The confidence and variability of USAT, LTI, and HRI

	Confidence (%)				**Variability (%)**			
	operator A	**operator B**	***t***	**p**	**operator A**	**operator B**	***t***	**p**
USAT	85±3.7	86±1.9	-3.279	0.025	6.9±5.98	4.7±3.20	2.970	0.021
LTI	94±9.0	96±8.2	-1.833	0.072	9.1±7.62	7.7±6.84	1.275	0.207
HRI	98±2.8	96±4.3	3.125	0.003	6.4±4.60	7.4±5.06	-1.191	0.238

Discussion

The results of this study demonstrate that the quantitative parameters of USAT, LTI, and HRI exhibit favorable reproducibility, offering reliable technical means for the ultrasound assessment of hepatic steatosis. In recent years, ultrasound quantitative techniques based on attenuation coefficient (AC) have shown promise in assessing hepatic steatosis [13-17]. These techniques, including the USAT technology utilized in this study, can quantitatively reflect liver tissue attenuation, with higher values indicating more severe hepatic steatosis. Controlled Attenuation Parameter (CAP), a parameter widely used in early clinical practice, has played a significant role in quantifying hepatic steatosis. However, its examination necessitates a specialized probe and lacks the guidance of real-time ultrasound imaging, which may limit its application in certain scenarios [18].

Beyond CAP, there are other ultrasound systems commercially available that estimate liver fat content based on AC algorithms, such as Attenuation Imaging (ATI), Ultrasound Derived Fat Fraction (UGAP), and Attenuation (ATT). These parameters have shown good to excellent intra- and inter-observer agreement in most studies, consistent with our findings [19-21]. However, the USAT technique in this study utilizes an advanced "full-domain acoustic field reduction" principle, enabling the restoration of true speed of sound and original attenuation information in liver ultrasound signals. By employing multi-frequency composite techniques, the USAT calculates accurate attenuation information, indicating its potential as a reliable method for quantitatively assessing hepatic steatosis alongside two-dimensional ultrasound examinations, providing a more precise diagnostic tool for clinical practice.

The value of a single index for evaluating the extent of hepatic steatosis remains limited. In this study, the LTI and HRI techniques were utilized in conjunction with USAT to enable a comprehensive, multiparameter assessment of hepatic steatosis in a quantitative manner. The texture of liver ultrasound images captures detailed structural information not visible to the naked eye, which is a valuable diagnostic tool [22]. Normal liver images exhibit a large, sparse liver parenchyma pattern, whereas liver steatosis manifests as poorly defined liver texture characterized by blurred patterns and smaller, denser, more intensified spots [23]. Consequently, the liver texture index value increases with the severity of hepatic steatosis. The LTI technique evaluates hepatic steatosis by analyzing liver texture data, demonstrating high diagnostic sensitivity for early-stage hepatic steatosis in previous studies [24].

The enhancement of echogenicity in grayscale ultrasound liver-kidney contrast is an important reference standard for the diagnosis of fatty liver, but it has limitations such as strong subjectivity and inability to perform quantitative assessment. The conventional method of determining the liver-kidney ratio involves comparing echo intensities between liver parenchyma and the right renal cortex. Studies indicate that the liver-kidney ratio can effectively quantify hepatic steatosis grades with favorable accuracy [25,26]. Nonetheless, inconsistencies in diagnosing hepatic steatosis exist due to variations in measurement depth and manufacturer-specific algorithms [27]. In our approach, we directly analyzed raw radiofrequency signals from the liver and kidneys to determine the liver-kidney ratio, independent of machine-related factors [13]. Our study demonstrated that the LTI and HRI values, derived from the same device using USAT, exhibit good reproducibility, laying the groundwork for future multi-parametric assessment of hepatic steatosis.

USAT assesses fat content by quantifying the ultrasound attenuation coefficient of the liver, showing a good correlation with CAP [28]. LTI offers a quantitative detection of texture changes associated with steatosis, which may be more sensitive to the microstructural changes in early liver steatosis. HRI provides an indirect measurement of steatosis by comparing the echogenicity of the liver and kidney and has been used as a semi-quantitative method for detecting liver steatosis, demonstrating a strong correlation with MRI-PDFF, and showing high diagnostic efficacy in diagnosing hepatic steatosis [29]. Although these techniques may have different specific cut-off values for diagnosing liver steatosis, they are consistent in their diagnostic direction. The combined use of multiple ultrasound techniques can enhance diagnostic accuracy and provide a more comprehensive assessment of hepatic steatosis. This aligns with the trend towards multiparametric ultrasound assessment, leveraging the unique advantages of different modalities to improve diagnostic and prognostic evaluation.

In this study, rigorous quality control measures were implemented. Patients were instructed to briefly hold their breath to ensure stability of the monitoring area and achieve a breathing motion index (M-STB Index) of 4 stars or higher, enhancing test accuracy and stability. The machine features a built-in reliability map (RLB MAP, Reliability Map) displayed alongside attenuation values, enabling operators to conduct real-time image quality checks. A reliability index of ≥80% was required, leading to improved reproducibility in this study. Test quantity was also scrutinized, revealing that reproducibility remained high whether tests were repeated 5 times or

3 times. Bao et al suggested that the optimal minimum number of measurements for the ATI technique is 4 times [30]. Similarly, our study suggests that for USAT, LTI, and HRI techniques, testing 3 times is sufficient in terms of reproducibility. However, this study focused on repeated sampling from the same region of interest (ROI), warranting further investigation into whether multiple sections and sampling points are necessary to enhance representativeness in assessing fatty liver.

Inter-operator reproducibility analysis revealed that the initial agreement between the two operators for the first 30 patients was suboptimal. However, after 30 cases of specialized training, there was a marked improvement in agreement to a satisfactory level, with operators who lacked prior ultrasound experience achieving good agreement comparable to that of their more experienced counterparts. This indicates that specialized training for operators can effectively enhance the reproducibility of the technique. As reported by Dag et al [31], the inter-observer reproducibility obtained through intercostal detection was excellent and slightly higher than the results of our study. This discrepancy may be attributed to the inclusion of less experienced beginners in our research. However, after training on 30 cases, the inter-observer agreement in our study also reached a good level, indicating a high clinical applicability of the USAT technology. It is recommended that a certain degree of training be provided to operators at the onset of testing these three quantitative parameters.

This study has some limitations. Firstly, the diagnostic efficacy of the technique was not assessed, necessitating the use of additional pathological findings as a criterion for a comprehensive evaluation of hepatic steatosis in future studies. Secondly, the sample size of the study was small, highlighting the need for further validation in a prospective, multicenter, large-sample study.

In **conclusion**, USAT, LTI, and HRI have shown good intra-operator reproducibility, and inter-operator reproducibility between the two operators reached a comparable level after 30 training cases.

Conflict of interest: none

Acknowledgements: This work was supported by the Shenzhen Longgang District Science and Technology InnovationSpecial Fund Project (No: LGKCYLWS2022033), the Joint Fund Project of AcademicInstitutions (No:YXLH2204),and the Hospital University United Fund of The Second Affiliated Hospital, School of Medicine, The Chinese University of Hong Kong, Shenzhen (No: HUUF-MS-202305).

References

1. Nan Y, An J, Bao J, et al. The Chinese Society of Hepatology position statement on the redefinition of fatty liver disease. J Hepatol 2021;75:454-461.
2. Zhou F, Zhou J, Wang W, et al. Unexpected Rapid Increase in the Burden of NAFLD in China From 2008 to 2018: A Systematic Review and Meta-Analysis. Hepatology 2019;70:1119-1133.
3. Iwashita H, Shakado S, Yoshimaru N, et al. Clinical Utility of Ultrasound-Guided Attenuation Parameter for the Detection and Quantification of Hepatic Steatosis in Patients with Fatty Liver Diagnosed by Computed Tomography. Ultrasound Med Biol 2022;48:1282-1289.
4. Liu F, Bi M, Jing X, et al. Multiparametric US for Identifying Metabolic Dysfunction-associated Steatohepatitis: A Prospective Multicenter Study. Radiology 2024;310:e232416.
5. Davison BA, Harrison SA, Cotter G, et al. Suboptimal reliability of liver biopsy evaluation has implications for randomized clinical trials. J Hepatol 2020;73:1322-1332.
6. Lu M, Wang MJ, Chen L. Advances in the application of elastography in noninvasive diagnosis of liver fibrosis in nonalcoholic fatty liver disease. J Clin Hepatol 2023;39:408-412.
7. Zhang Y, Li B, Liu N, Wang P, He J.. Evaluation of Different Anthropometric Indicators for Screening for Nonalcoholic Fatty Liver Disease in Elderly Individuals. Int J Endocrinol 2021;2021:6678755.
8. Li J, Li XF, Yan N, Liu LJ. Evaluation the screening value of obesity-related indices for non-alcoholic fatty liver disease. Chinese J Gen Pract 2023,21:195-198.
9. Wang X, Bamber JC, Esquivel-Sirvent R, et al. Ultrasonic Sound Speed Estimation for Liver Fat Quantification: A Review by the AIUM-RSNA QIBA Pulse-Echo Quantitative Ultrasound Initiative. Ultrasound Med Biol 2023;49:2327-2335.
10. Hernaez R, Lazo M, Bonekamp S, et al. Diagnostic accuracy and reliability of ultrasonography for the detection of fatty liver: a meta-analysis. Hepatology 2011;54:1082-1090.
11. Lee CM, Yoon EL, Nakajima A, et al. A Reappraisal of the Diagnostic Performance of B-Mode Ultrasonography for Mild Liver Steatosis. Am J Gastroenterol 2023;118:840-847.
12. Ferraioli G, Barr RG, Berzigotti A, et al. WFUMB Guidelines/Guidance on Liver Multiparametric Ultrasound. Part 2: Guidance on Liver Fat Quantification. Ultrasound Med Biol 2024;50:1088-1098.
13. Dong Y, Wang WP. Detection and application prospects of ultrasound techniques for hepatic steatosis. Oncoradiology 2023;32:317-323.
14. Karlas T, Petroff D, Sasso M, et al. Individual patient data meta-analysis of controlled attenuation parameter (CAP) technology for assessing steatosis. J Hepatol 2017;66:1022-1030.
15. De Robertis R, Spoto F, Autelitano D, et al. Ultrasound-derived fat fraction for detection of hepatic steatosis and quan-

tification of liver fat content. Radiol Med 2023;128:1174-1180.
16. Xia T, Du M, Li H, et al. Association between Liver MRI Proton Density Fat Fraction and Liver Disease Risk. Radiology 2023;309:e231007.
17. Park J, Lee JM, Lee G, Jeon SK, Joo I. Quantitative Evaluation of Hepatic Steatosis Using Advanced Imaging Techniques: Focusing on New Quantitative Ultrasound Techniques. Korean J Radiol 2022;23:13-29.
18. Ferraioli G, Tinelli C, Lissandrin R, et al. Interobserver reproducibility of the controlled attenuation parameter (CAP) for quantifying liver steatosis. Hepatol Int 2014;8:576-581.
19. Ferraioli G, Maiocchi L, Raciti MV, et al. Detection of Liver Steatosis With a Novel Ultrasound-Based Technique: A Pilot Study Using MRI-Derived Proton Density Fat Fraction as the Gold Standard. Clin Transl Gastroenterol 2019;10:e00081.
20. Jeon SK, Lee JM, Joo I, et al. Prospective Evaluation of Hepatic Steatosis Using Ultrasound Attenuation Imaging in Patients with Chronic Liver Disease with Magnetic Resonance Imaging Proton Density Fat Fraction as the Reference Standard. Ultrasound Med Biol 2019;45:1407-1416.
21. Fujiwara Y, Kuroda H, Abe T, et al. The B-Mode Image-Guided Ultrasound Attenuation Parameter Accurately Detects Hepatic Steatosis in Chronic Liver Disease. Ultrasound Med Biol 2018;44:2223-2232.
22. Zhong X, Li JS, Chen ZJ, et al. Texture analysis of diffusion-weighted magnetic resonance imaging to identify atypically enhanced small hepatocellular carcinoma and dysplastic nodules under the background of cirrhosis. Zhonghua Gan Zang Bing Za Zhi 2020;28:37-42.
23. Jian ZC, Long JF, Liu YJ, et al. Diagnostic value of two dimensional shear wave elastography combined with texture analysis in early liver fibrosis. World J Clin Cases 2019;7:1122-1132.
24. Jung EM, Dong Y, Jung F. Current aspects of multimodal ultrasound liver diagnostics using contrast-enhanced ultrasonography (CEUS), fat evaluation, fibrosis assessment, and perfusion analysis - An update. Clin Hemorheol Microcirc 2023;83:181-193.
25. Kjaergaard M, Lindvig KP, Hansen CD, Detlefsen S, Krag A, Thiele M. Hepatorenal Index by B-Mode Ratio Versus Imaging and Fatty Liver Index to Diagnose Steatosis in Alcohol-Related and Nonalcoholic Fatty Liver Disease. J Ultrasound Med 2023;42:487-496.
26. Moret A, Boursier J, Houssel Debry P, et al. Evaluation of the Hepatorenal B-Mode Ratio and the "Controlled Attenuation Parameter" for the Detection and Grading of Steatosis. Ultraschall Med 2022;43:479-487.
27. Ferraioli G, Kumar V, Ozturk A, Nam K, de Korte CL, Barr RG. US Attenuation for Liver Fat Quantification: An AIUM-RSNA QIBA Pulse-Echo Quantitative Ultrasound Initiative. Radiology 2022;302:495-506.
28. Jiang M, Zhang X, Wu X, et al. The diagnostic value of novel ultrasound attenuation analysis in detecting liver steatosis identified by the controlled attenuation parameter: a diagnostic accuracy study. Ann Transl Med 2023;11:38.
29. Pirmoazen AM, Khurana A, Loening AM, et al. Diagnostic Performance of 9 Quantitative Ultrasound Parameters for Detection and Classification of Hepatic Steatosis in Nonalcoholic Fatty Liver Disease. Invest Radiol 2022;57:23-32.
30. Bao J, Lv Y, Wang K, et al. A Comparative Study of Ultrasound Attenuation Imaging, Controlled Attenuation Parameters, and Magnetic Resonance Spectroscopy for the Detection of Hepatic Steatosis. J Ultrasound Med 2023;42:1481-1489.
31. Dag N, Igci G, Yagin FH, Hanci MS, Kutlu R. Interobserver Reproducibility of Ultrasound Attenuation Imaging Technology in Liver Fat Quantification. J Clin Ultrasound 2024 Oct 22. doi:10.1002/jcu.23877.