Med Ultrason 2024, Vol. 26, no. 3, 242-247
DOI: 10.11152/mu-4392

Utrasound as a method for confirming the positioning of enteral catheters in critically ill patients

Ronan de Souza[1,4], Cecilia Gómez Ravetti[1,2,4], Rafael Silva e Castro[2], Elio Furbino Frossard[2], Isabella Santanna dos Anjos[3,4], Angélica Gomides dos Reis Gomes[2,4], Paula Frizera Vassallo[1,4], Vandack Nobre[1,2,4]

[1]Intensive Care Unit, Hospital das Clínicas of the Universidade Federal de Minas Gerais, [2]Internal Medicine Department, School of Medicine, Universidade Federal de Minas Gerais, [3]Bed Management Team, Hospital das Clínicas of the Universidade Federal de Minas Gerais, [4]NIIMI (Núcleo Interdisciplinar de Investigação em Medicina Intensiva), Belo Horizonte, Minas Gerais, Brazil

Abstract

Aim: To evaluate the agreement between the bedside ultrasound in a single epigastric window and the plain X-ray to confirm the positioning of the enteral catheter in critically ill patients. **Material and methods**: This was an observational, cross-sectional study conducted in two Intensive Care Units of a university hospital. The ultrasound exams were carried out immediately after the introduction of the enteral catheter, using only the epigastric window, with an injection of 5 ml of air associated with 5 ml of saline solution. In all cases, the plain radiography was taken to confirm the positioning of the enteral catheter and to define the beginning of nutritional therapy. **Results**: This study included 83 patients, the positioning of the enteral catheter was confirmed by plain radiography in all cases and by ultrasound in 81 (97.6%) patients. The median duration of the ultrasound exam was 2 (2-3) minutes, while the time spent between the request for the X-ray and the release of the exam for a doctor's appointment was 225 (120-330) minutes. **Conclusion:** Bedside ultrasound proved to be an effective, quick, and safe method to confirm the position of the enteral catheter in critically ill patients.

Keywords: enteral nutrition; ultrasound; gastrointestinal intubation; nasoenteral catheter

Introduction

The nutrition of critically ill patients is an integral part of the adjuvant treatment of a series of diseases that lead to a patient's hospitalization in the Intensive Care Unit (ICU). The enteral catheter (EC) is the most commonly used alternative for nutritional therapy in this population [1]. The catheter is generally inserted into the nostrils or, less commonly, through the mouth, and its incorrect positioning in the respiratory tract or above the lower esophageal sphincter can result in complications, including pneumonia, empyema, pneumothorax, pulmonary hemorrhage, and death [2].

Different methods can be used to confirm the positioning of the EC, such as the measurement of the pH in the aspirated material, visual evaluation of gastric reflux, measurement of the length of the catheter, tests of biochemical markers (concentrations of bilirubin, pepsin, or trypsin), and imaging tests (plain radiography) [3], with this final option being the most commonly used in ICU [3-5].

Nevertheless, the use of plain radiography is associated with exposure of the patient and the medical team to ionizing radiation; the need to mobilize patients to acquire the images, with the risk of displacing the EC and other invasive devices (vascular catheters, orotracheal tubes, etc.); in addition, it can potentially cause patient

Received 01.11.2023 Accepted 21.05.2024
Med Ultrason
2024, Vol. 26, No 3, 242-247
Corresponding author: Ronan de Souza, HC UFMG
Hospital das Clínicas da
Universidade Federal de Minas Gerais,
110 Av. Professor Alfredo Balena, Santa Efigênia,
30130-100 Belo Horizonte (MG), Brasil
Phone: +55(31) 987946316
E-mail: ronansolza@yahoo.com.br

discomfort and clinical instability [2,3,6]. Moreover, in most units, plain radiographs are performed by a technician from the radiology department, which can lead to delays in carrying out the exam and, in consequence, lengthen the time to initiate the enteral nutrition.

The bedside ultrasound (BUS) represents a safe, practical, accessible, and easily-executable technique, virtually free of risks directly associated with the procedure. Studies that investigate the role of ultrasound exams in confirming the positioning of the EC are scarce and tend to focus on reduced sample sizes, especially those that use only one exam window.

The present study aimed to evaluate the agreement between the BUS and the plain radiography to confirm the positioning of the EC in critically ill patients, as well as to analyze the potential impact of this exam on the time to start the enteral nutrition.

Material and method

Patients and setting

This work was an observational, cross-sectional study conducted in two ICUs (total of 32 beds) of the Hospital das Clínicas of the Universidade Federal de Minas Gerais (HC-UFMG), in Belo Horizonte, Brazil, from July 2020 to March 2021. We included a convenience sample of patients in a sequential manner, since they were 18 years of age or over and had received the recommendation of enteral nutrition from the medical team. Excluded from this study were patients who, upon hospitalization, already had an EC; patients who were in the post-operative period of esophageal, gastric, or head and neck surgery; dying patients (prediction of death within the next 24 hours); and patients with a body mass index (BMI) >40 Kg/m^2.

This study was approved by the UFMG Research Ethics Committee (logged under CAAE: 31336920.5.0000.5149), and all participants or their legal guardians agreed to participate in this study by signing the informed consent form.

Study procedures

Demographic and clinical data related to the acute condition and comorbidities were collected. The severity of the illness was defined by the Sequential Organ Failure Assessment (SOFA) scores [7] and the Acute Physiology and Health Evaluation (APACHE-II) [8]. We also collected data referent to the mortality rate in the ICU and at 28 days. Each patient was included once, regardless of the number of EC inserted during the ICU stay. Data were collected from electronic medical records.

All EC insertions were performed via the nasoenteric route, being performed by nurses, following the protocol used in the ICU. In short, the catheter was measured from the point of the nose to the earlobe and from the earlobe to the xiphoid process, and then inserted in the nostril or the oral cavity in the direction of the pharynx, with its distal extremity positioned blindly in the stomach.

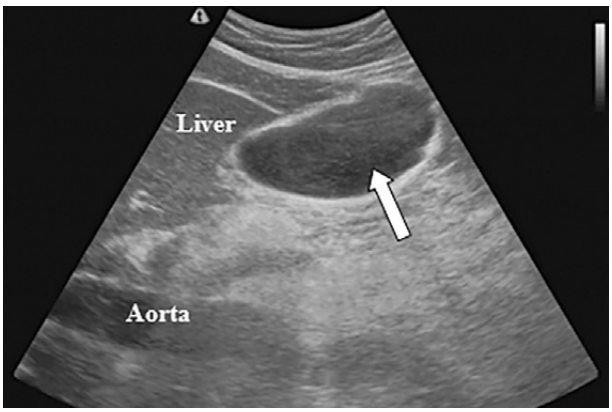

Fig 1. Image of the ultrasound of the gastric antrum (white arrow), with the main ultrasound reference points: left lobe of the liver and aorta.

Ultrasound for the confirmation of the positioning of the EC

The gastric BUS exams were performed immediately after the insertion of the EC. Two portable ultrasound devices were used: Terason t3000® and GE-Logic-V2®, with a curvilinear transducer (2-5MHz) in the epigastric window (below the xiphoid process), applied to the skin in a longitudinal position with the marker pointing to the cephalic direction. The initial depth used was 13 to 20 cm, adjusted during the exam, as needed. The gastric antrum was identified in the sagittal plane, using the left lobe of the liver anteriorly and the aorta posteriorly as its reference (fig 1). The patients were placed in the supine position, with the headboard raised to 30 degrees during the exam.

After obtaining the ideal ultrasound window, the positioning of the EC was confirmed through the visibility of the entrance of air and saline solution (5 ml of air and 5 ml of saline solution) in the stomach, injected through the EC. The ultrasound exams were performed by two of the authors, CGR and RS, both with ample experience in conducting BUS exams. After defining the ultrasound protocol, each examiner carried out another 10 exams for training, independently, followed by 10 exams together to certify agreement between them.

In all patients included in this study, chest-abdominal plain radiography was requested to verify the positioning of the EC shortly after its passage, according to the local protocol. The images were displayed in the digital imaging system used in the hospital and the decision to initiate or not the enteral nutrition was left at the discretion of

the medical care team. The investigators did not interfere with the patient management and did not modify the current local protocols regarding the confirmation of the EC positioning.

Statistical analysis

The collected data were analyzed using the SPSS program (SPSS Statistics 22.0, Armonk, NY: IBM Corp. USA). First, the descriptive analysis of the data was performed, with the evaluation of the distribution and the central tendency, in the case of continuous variables, and the analysis of proportions for the categorical variables. The continuous variables were presented as mean (standard deviation) or median (Q1-Q3) according to their distribution, normal or non-normal, defined by direct graph visualization and the Shapiro-Wilk test. Association tests were performed using the Chi-squared or the Fisher exact test for categorical variables and the Mann-Whitney test for continuous variables, as recommended. The bicaudal value of $p<0.05$ was considered significant in all analyses.

Results

During the period of this study, 103 patients were evaluated for potential inclusion, of which 83 were finally included. The main reasons for non-inclusion were: already having an EC at the time of inclusion in this study (7 patients), BMI >40 Kg/m² (4 patients), immediate post operative period of esophago-gastric surgery (3 patients) or head and neck surgery (1 patient), and dying patients (2 patients). Three patients refused to participate in the study and did not sign the informed consent form.

Considering the 83 patients included in the final analysis, the median age (Q1-Q3) was 60 (50-70) years; the female sex was the most frequent; and the median BMI was of 26.4 (23.8-30.1) kg/m^2. The most common comorbidities were arterial hypertension (55 patients, 66.3%), diabetes mellitus (20 patients, 24.4%), obesity (22 patients, 26.5%), chronic kidney disease requiring dialysis (14 patients, 16.9%), congestive heart failure (23 patients, 28%), solid neoplasia (15 patients, 18.3%), and chronic obstructive pulmonary disease / asthma (13 patients, 15%). The mortality rate in the ICUs and at 28 days was 50.6% (n=42) and 65.1% (n=54), respectively. The median length of stay in the hospital was 28 (17-52) days, while in the ICU, was 13 (9-18) days. The main characteristics of the patients included in this study are shown in Table I.

Table I. Main characteristics of the included patients

Characteristics	Values
Age, years	60 (50-70)
Sex, female	43 (51.8)
BMI, kg/cm^2	26.4 (23.8-30.1)
Comorbidities	
COVID-19	37 (45.1)
SAH	55 (66.3)
Diabetes mellitus	20 (24.4)
Obesity	22 (26.5)
CKD requiring dialysis	14 (16.9)
Heart failure	23 (28)
Solid neoplasia	15 (18.3)
Hematological neoplasia	6 (7.3)
Cirrhosis	7 (8.6)
COPD/Asthma	13 (15)
Vascular disease	8 (9.8)
Others	30 (36.6)
APACHE II, points	22 (15-26)
SOFA, points	8 (5-10)
Clinical hospitalizations	63 (75.9)
Need for IMV	71 (85.5)
Use of vasopressor	46 (55.4)
ICU mortality rate	42 (50.6)
Hospital mortality rate	54 (65.1)
Hospital stay, days	28 (17-52)
Stay in ICU, days	13 (9-18)

The data are presented in median (Q1-Q3) and n (%). BMI: body mass index; SAH: systemic arterial hypertension; CKD: Chronic kidney disease; COPD: Chronic obstructive pulmonary disease; APACHE II: Acute Physiology and Health Evaluation; SOFA: Sequential Organ Failure Assessment; IMV: Invasive mechanical ventilation; ICU: Intensive Care Unit.

BUS and plain radiography to verify the positioning of the enteral catheter

The blind insertion of the EC took place without complications in all of the participants of the study; this device was implanted through the patients' nostrils in most cases (94%). The positioning of the EC was confirmed in all cases by the chest-abdominal plain radiography and in 81 (97.6%) patients by BUS (fig 2a-c). The interference of gases was the reason behind the non-confirmation of the EC positioning by the BUS in two patients. The median time to confirm the EC positioning with the BUS was 2 (2-3) minutes, as compared to 225 (120-330) minutes for X-ray confirmation (Table II).

In 17 (20,4%) patients, in addition to the visualization of the entrance of air plus saline solution injected through the EC in the stomach, it was also possible to view the EC directly through the BUS (fig 2d). No patient presented complications or adverse events related to the ultrasound and radiography exams, nor did they require any type of analgesic or additional sedative or presented any new hemodynamic instability. Epigastric auscultation was positive in 82 (98.8%) patients and gastric stasis was present in 40 (48.2%).

Table II. Characteristics related to the implantation of the enteral catheter in the patients of this study

Characteristics	Values
Implantation through the nostrils	78 (94%)
Positive epigastric auscultation	82 (98.8%)
Return of gastric stasis	40 (48.2%)
Confirmation of EC positioning	
X-ray	83 (100%)
BUS	81 (97.6%)
Duration of BUS, minutes, median (Q1-Q3)	2 (2-3)
Time between the request for an X-ray and the release of the image for the doctor's appointment, minutes, median (Q1-Q3).	225 (120-330)

BUS: Bedside Ultrasound; EC: Enteral catheter

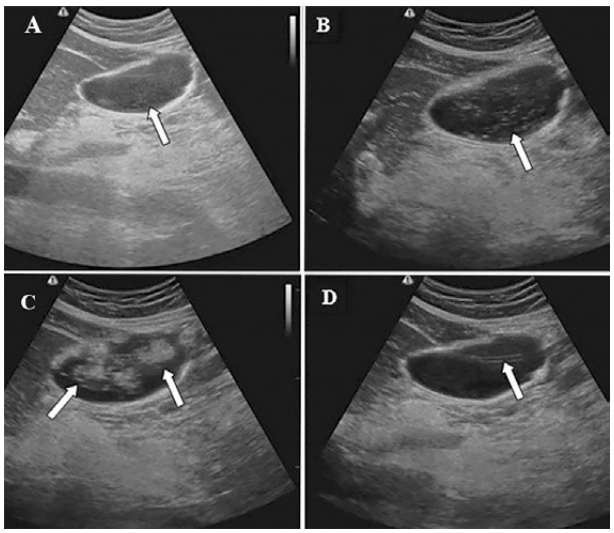

Fig 2. Ultrasound image in epigastric window: A) Ultrasound before injection of air and saline solution in the gastric antrum (white arrow); B) and C) Ultrasound after injection of air and saline solution in the gastric antrum (white arrow); D) direct visualisation of the catheter by ultrasound (arrow).

Discussion

In this study conducted with 83 critically ill adults with enteral nutrition recommendation, the BUS, using a single epigastric window, was capable of confirming the EC position in 97.6% of the cases. The median time for the confirmation of the EC position by ultrasound was only 2 minutes. Performing this exam was not associated with any adverse events. This study contributes with novel insights to this field, complementing previous research by demonstrating that ultrasound is a safe, practical, and easy-to-perform method to confirm enteral catheter positioning.

Studies on the use of BUS to confirm the positioning of the EC are scarce in the literature, included a low number of patients in most cases, and only a few tested protocols using a single exam window. For example, Mori et al, in a study with 12 pediatric patients, combining the esophageal and epigastric windows, were capable of identifying the positioning of the EC in all of the patients [9]. In 114 adult patients, Zatelli et al demonstrated a sensitivity of 100% when using four windows (esophageal, esophagogastric, epigastric: antrum and gastric fundus) [5]. In a systemic review including 10 studies, Tsujimoto et al observed a sensitivity of 91-98% and a specificity of 56-100%. It should be stressed that, despite the favorable results observed in these studies, the use of protocols with multiple ultrasound windows to verify the positioning of the EC can increase the technical demand to perform this exam, as well as prolong the time for its execution [2].

Few experiences using a single window have been published. In one recent study with 41 patients undergoing invasive mechanical ventilation, conducted by Nedel et al, the authors confirmed the EC positioning in all of the patients, using only the epigastric window [6]. Testing similar protocol, again in mechanically ventilated patients, Gok et al showed that the ultrasound was effective in 92.8% of the cases; however, there was a need to use additional patient sedation in order to perform the exam [10].

The time needed to confirm the positioning of the EC with the BUS was quite short in the present study, more exactly, 100 times shorter than the time spent between the plain radiography request and its release in the imaging system. This result regarding the BUS is possibly due to the expertise of the examiners responsible for the exams, in addition to the use of a single ultrasound window. Vigneau et al, using only the epigastric window, spent, on average, 5 min to confirm the positioning of the EC in 35 patients hospitalized in ICUs. In their study, the ultrasound was effective in 34 of the 35 procedures (sensitivity 97%), when compared to the X-ray [11]. A similar time was spent in another recent study conducted with 30 critically ill patients, which also evaluated only the epigastric window [12].

Even in studies that used two or more ultrasound windows, the time to perform the exam was shorter than the interval required for the X-ray confirmation. For example, in one study published in 2017, which evaluated the precision of BUS to verify the correct positioning of the EC, using four windows (longitudinal and cross-sectional scan of the esophagus, gastroesophageal junction, antrum, and gastric fundus) the average time required to perform the exam was 10 minutes [5]. The time recorded between the request for the X-ray and the release of the digital image for the assistant physicians' appointment –

approximately 225 minutes – in the present study may have been longer than the average observed in other institutions, due local to logistic aspects of the main institution of this study. Nevertheless, prior studies conducted in other institutions, have also observed that the X-ray can impose an excessive delay for the beginning of enteral nutrition - time spent to perform the exam varying from 162 to 180 min - and can represent an excessive use of healthcare resources [6,11].

In two patients of the present study, it was not possible to confirm the positioning of the EC. The two patients had a BMI of above 32 and presented abdominal distension with a major interference caused by gases. Furthermore, in one of these patients, the epigastric auscultation proved to be negative. Similar difficulties were reported in previous studies [5,12]. The distribution of BMI values observed in the present study was similar to that found by other authors [6,12].

Critically ill patients, such as those included in this study, have a greater potential to benefit from the use of effective tools that are easy to execute and that can minimize the mobility of unstable patients. This is also valid for the context of the pandemic, considering that nearly half of the patients included in this study had confirmed COVID-19 [13,14]. In addition to these benefits, the BUS avoids exposuring patients and the medical care team to ionizing radiation. As regards the costs, there is no true definition of the real cost of the ultrasound exam to verify the positioning of the EC. However, since many ICUs currently have ultrasound devices easily available to perform other evaluations and routine procedures, the use of this equipment to verify the EC positioning would add only minimal costs to the healthcare system. Furthermore, the training necessary to perform the BUS is simple, especially if the protocol calls for the use of a single epigastric window, which can involve medical and nursing professionals [5].

This study has a number of limitations. First, the BUS technique commonly depends on the operator and the quality of the equipment, requiring a certain learning curve and a standardization of the technique used in order to obtain an appropriate image. However, the same protocol was used in all of the exams, which were performed by two professionals who were homogeneously trained in epigastric ultrasound exams geared toward the localization of EC. Second, this study was conducted in a single center and the sample size was relatively small, limiting the external validity of our findings. In clinical practice, radiography is the gold standard method for confirming the positioning of the enteral catheter [5], and the use of ultrasound as a confirmation method should be tested in studies of non-inferiority.

Conclusion

In conclusion, according to the present study's results, the BUS is a simple and effective tool to confirm the positioning of the EC in critically ill patients, presenting many potential advantages in relation to the chest-abdominal plain radiography. Randomized clinical trials comparing the effectiveness and safety of the BUS and the X-ray in this context are highly desirable.

Conflict of interest: none

Acknowledgements: This work was supported by the National Council for Scientific and Technological Development (CNPq), the Ministry of Health (MEC/SESU - COVID-19 Task Force), and the Universidade Federal de Minas Gerais (UFMG). We would like to thank the Intensive Care Unit teams for their support in conducting this study.

References

1. Metheny NA, Krieger MM, Healey F, Meert KL. A review of guidelines to distinguish between gastric and pulmonary placement of nasogastric tubes. Heart Lung 2019;48:226-235.
2. Tsujimoto H, Tsujimoto Y, Nakata Y, Akazawa H, Kataokav Y. Ultrasonography for confirmation of gastric tube placement. Cochrane Database Syst Rev 2017;4:CD012083.
3. Lin T, Gifford W, Lan Y, et al. Diagnostic accuracy of ultrasonography for detecting nasogastric tube (NGT) placement in adults: A systematic review and meta-analysis. Int J Nurs Stud 2017;71:80-88.
4. Beghetto MG, Anziliero F, Leães DM, de Mello ED. Feeding tube placement: auscultatory method and x-ray agreement. Rev Gaúcha Enferm 2015;26:98-103.
5. Zatelli M, Vezzali N. 4-Point ultrasonography to confirm the correct position of the nasogastric tube in 114 critically ill patients. J Ultrasound 2017;20:53-58.
6. Nedel WL, Jost MNF, Filho JWF. A simple and fast ultrasonographic method of detecting enteral feeding tube placement in mechanically ventilated, critically ill patients. J Intensive Care 2017;5:55.
7. Vincent JL, Moreno R, Takala J, et al. The SOFA (Sepsis-related Organ Failure Assessment) score to describe organ dysfunction/ failure. On behalf of the Working Group on Sepsis-Related Problems of the European Society of Intensive Care Medicine. Intensive Care Med 1996;22: 707–710.
8. Knaus WA, Draper EA, Wagner DP, Zimmerman JE. APACHE II: A severity of disease classification system. Crit Care Med 1985;13:818-829.
9. Mori T, Takei H, Ihara T, Hagiwara Y, Nomura O. Ultrasound-guided nasogastric tube placement in a pediatric emergency department. J Clin Ultrasound 2021;49:106-109.

10. Gok F, Kilicaslan A, Yosunkaya A. Ultrasound-guided nasogastric feeding tube placement in critical care patients. 2015;30:257-260.
11. Vigneau C, Baudel JL, Guidet B, Offenstadt G, Maury E. Sonography as an alternative to radiography for nasogastric feeding tube location. Intensive Care Med 2005;31:1573-1572.
12. Li G , Pan Y, Zhou J, Tong Z, Ke L, Li W. Enteral nutrition tube placement assisted by ultrasonography in patients with severe acute pancreatitis: A novel method for quality improvement. Medicine (Baltimore) 2017;96:e8482.
13. De Souza R, Gomez Ravetti C, Silva E, et al. Ultrasound as an alternative bedside tool to quickly confirm the position of the enteral catheter in the context of the COVID-19 pandemic. Med Ultrason 2021;23:371-372.
14. Qian A, Xu S, Lu X, Tang L, Zhang M, Chen X. Rapid positioning of nasogastric tube by ultrasound in COVID-19 patients. Crit Care 2020;24:568.