Original papers

Med Ultrason 2024, Vol. 26, no. 3, 264-269
DOI: 10.11152/mu-4380

Evaluation of the correlation of wall elasticity between different sections of radial artery by velocity vector imaging

Ge Tong, Yihua Gao, Dandan Yuan

Department of Ultrasound, The Affiliated Hospital of Yanbian University, Yanji, Jilin, China

Abstract

Aim: This study aimed to evaluate the correlation between the elasticity of the anterior and posterior walls of the radial artery in different sections using velocity vector imaging. **Material and methods:** In this retrospective analysis, 30 healthy people who underwent physical examination in our hospital from January 2022 to January 2023 were analyzed offline by velocity vector imaging technology. The following parameters were assessed: peak systolic strain (Ss; %), peak diastolic strain (Sd; %), peak systolic strain rate (SRs; 1/s), and peak diastolic strain rate (SRd; 1/s). Elastic function was evaluated by analyzing the systolic and diastolic motion of the arterial walls. **Result:** In the long-axis sections, there was a significant positive correlation between Ss, SRs, and SRd of both the anterior and posterior walls ($r=0.531$, $r=0.803$, and $r=0.898$, all $p<0.01$). Additionally, Sd showed a positive correlation ($r=0.402$, $p<0.05$). In the short-axis sections, there was a significant and positive correlation between SRs and SRd of both walls ($r=0.762$, $r=0.667$, both $p<0.01$). Furthermore, a positive correlation was found between SRd in the long-axis and short-axis sections of the anterior wall ($r=0.382$, $p<0.05$). **Conclusions:** Velocity vector imaging is a valuable tool for assessing the elasticity of the radial artery in different sections, and the longitudinal SRd in the long-axis section may serve as a highly sensitive and accurate parameter for assessing changes in wall elastic function during the occurrence of radial artery lesions.

Keywords: elasticity; radial artery; velocity vector imaging

Introduction

Radial artery calcification is an independent risk factor for arteriovenous fistula (AVF) failure in patients with end-stage renal disease (ESRD), and it is also highly prevalent in this patient population. Therefore, it is crucial to assess the elastic state of the radial artery before surgery. Velocity vector imaging (VVI) is a recently developed ultrasound technique that enables the evaluation of the biomechanical motion and elastic function of blood vessels. It can quantitatively measure tissue motion parameters, including strain (S) and strain rate (SR), which can be used to assess the systolic and diastolic function of the local vessel wall. Moreover, VVI can assess the elasticity of arteries, providing valuable information for disease management and prevention of complications [1]. Although the VVI technique has been primarily used to evaluate wall function in elastic arteries such as the common carotid artery [2], there is limited literature on its application in assessing radial artery elasticity.

This study aims to investigate the difference and correlation in the elastic function between the anterior and posterior walls of the radial artery and to explore the correlation between the elastic function of the long and short axial sections of the artery, using the VVI technique. The findings of this study can serve as a basis for the clinical quantitative assessment of radial artery wall elasticity.

Received 03.01.2024 Accepted 16.03.2024
Med Ultrason
2024, Vol. 26, No 3, 264-269
Corresponding author: Yihua Gao
Department of Ultrasonic Diagnosis,
Yanbian University Hospital,
1327 Juzi Street, Yanji,
Jilin 133000, P.R. China
Phone:13843367889
E-mail: gyh20021997@163.com

Materials and methods

Study population

The retrospective study was approved by our hospital's Ethics Committee and waived the requirement of

informed consent. In this retrospective study, 30 people who underwent physical examination at the Affiliated Hospital of Yanbian University between January 2022 and January 2023 were retrieved from our ultrasound database to exclude diseases that may affect the vascular system, such as hypertension, hyperlipidemia, diabetes, and hepatic and renal insufficiency. The average age was 32.07±4.82 years, including 13 females and 17 males.

Ultrasound imaging

We employed a Siemens Sequoia ultrasound scanner with a linear array transducer (18L6, 4.6-17.8 MHz). The scanner was equipped with Siemens Syngo US Workplace offline workstation, which had VVI processing software installed.

Off-line VVI analysis was performed on the long-axis and short-axis sections of the radial artery, and the media-external membrane junction of the arterial walls was traced respectively. The relevant data were obtained (fig 1-4), and the VVI processing software was utilized to repeat the analysis five times, taking the average value of these data.

Statistical analysis

The data were analyzed using the SPSS 26.0 statistical software. The measurement data are expressed as mean ± standard deviation (x ± s). The difference between the anterior and posterior walls was analyzed using a t-test. Pearson method analyzed the correlation between the long-axis and short-axis, as well as the anterior and posterior walls. A p-value less than 0.05 is considered statistically significant.

Results

Difference and correlation of wall elasticity indexes between systolic and diastolic periods in the anterior and posterior walls of the radial artery in long-axis sections

No significant differences were observed in the values of S and SR during the systolic period, as well as the values of S and SR during the diastolic period, between the anterior and posterior walls ($p>0.05$) (Table I).

The Ss, SRs, and SRd of the anterior wall and posterior wall were significantly positively correlated ($p<0.01$), and Sd was positively correlated ($p<0.05$) (Table II).

Difference and correlation of wall elasticity indexes between systolic and diastolic periods in the anterior and posterior walls of the radial artery in short-axis sections

No statistically significant differences were found between the anterior and posterior walls in terms of S and SR during both the systolic and diastolic periods ($p>0.05$) (Table III).

The SRs and SRd of the anterior wall and posterior wall exhibited a significant positive correlation ($p<0.01$).

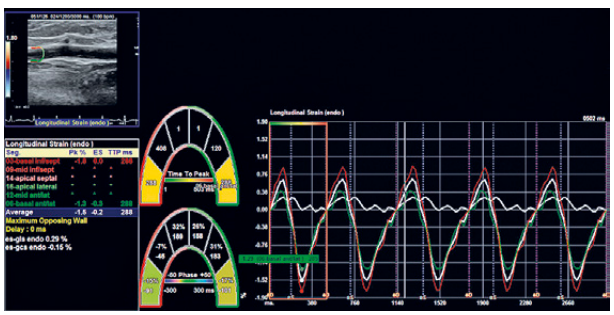

Fig 1. The VVI technique was used to analyze the strain in the long-axis section of the radial artery.

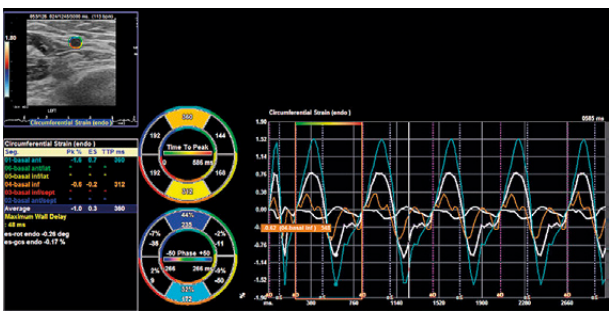

Fig 2. The VVI technique was used to analyze the strain in the short-axis section of the radial artery.

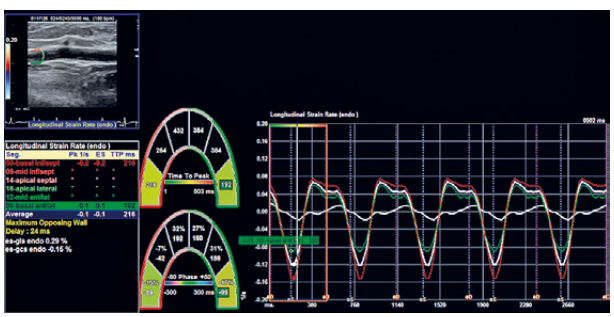

Fig 3. The VVI technique was used to analyze the strain rate in the long-axis section of the radial artery.

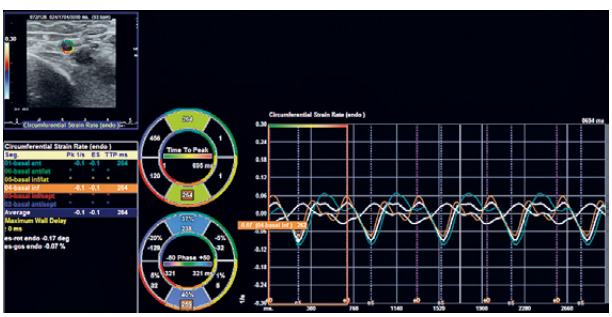

Fig 4. The VVI technique was used to analyze the strain rate in the short-axis section of the radial artery.

However, there was no observed correlation between the Ss and Sd ($p>0.05$) (Table IV).

Correlation of elasticity indexes between the long-axis and short-axis sections of the anterior radial artery during systolic and diastolic periods

There was a positive correlation between the SRd of the anterior wall and the long-axis and short-axis sections ($p<0.05$). However, there was no significant correlation between the Ss, SRs, and Sd ($p>0.05$) (Table V).

Correlation of elasticity indexes between the long-axis and short-axis section of the posterior radial artery during systolic and diastolic periods

There was no significant correlation between the values of S and SR during the systolic period and those during the diastolic period ($p>0.05$) (Table VI).

Discussion

Previous reports [3-4] indicate that approximately 50% of patients with ESRD experience mortality attributed to cardiovascular disease. The presence of medial arterial calcification can contribute to the increased incidence and mortality of cardiovascular disease. Therefore, early detection of changes in vascular elastic function is essential for reducing the occurrence of adverse cardiovascular events. Vascular function and plaque formation were traditionally assessed using conventional ultrasound, which measured parameters such as intima-media thickness, vessel diameter, and blood flow velocity, among others [5]. However, subclinical changes in arterial hardness occur before the emergence of atherosclerotic

Table I. Difference in wall elasticity indexes between systolic and diastolic periods in the anterior and posterior walls of the radial artery in long-axis sections.

Part	Ss/%	SRs/(1/s)	Sd/%	SRd/(1/s)
Anterior wall	-2.350±1.401	-0.142±0.115	1.950±1.386	0.137±0.080
Posterior wall	-2.032±1.415	-0.133±0.101	2.075±1.372	0.134±0.103
t	-.875	-.301	-0.351	0.151
p	0.385	0.764	0.727	0.880

The data are mean±SD. Ss, peak systolic strain; Sd, peak diastolic strain; SRs, peak systolic strain rate; SRd, peak diastolic strain rate.

Table II. Correlation of wall elasticity indexes between systolic and diastolic periods in the anterior and posterior walls of the radial artery in long-axis sections.

Part	Ss/%	SRs/(1/s)	Sd/%	SRd/(1/s)
Anterior wall	-2.350±1.401	-0.142±0.115	1.950±1.386	0.137±0.080
Posterior wall	-2.032±1.415	-0.133±0.101	2.075±1.372	0.134±0.103
r	0.531**	0.803**	0.402*	0.898**
P	0.003	0.001	0.028	0.001

The data are mean±SD. *p<0.05. **p<0.01. Ss, peak systolic strain; Sd, peak diastolic strain; SRs, peak systolic strain rate; SRd, peak diastolic strain rate.

Table III. Difference in wall elasticity indexes between systolic and diastolic periods in the anterior and posterior walls of the radial artery in short-axis sections.

Part	Ss/%	SRs/(1/s)	Sd/%	SRd/(1/s)
Anterior wall	-1.214±0.647	-0.064±0.040	0.854±0.707	0.063±0.054
Posterior wall	-1.112±0.762	-0.069±0.050	1.079±0.617	0.065±0.040
t	0.557	0.401	-1.318	-0.115
p	0.580	0.690	0.193	0.909

The data are mean±SD. Ss, peak systolic strain; Sd, peak diastolic strain; SRs, peak systolic strain rate; SRd, peak diastolic strain rate.

Table IV. Correlation of wall elasticity indexes between systolic and diastolic periods in the anterior and posterior walls of the radial artery in short-axis sections.

Part	Ss/%	SRs/(1/s)	Sd/%	SRd/(1/s)
Anterior wall	-1.214±0.647	-0.064±0.040	0.854±0.707	0.063±0.054
Posterior wall	-1.112±0.762	-0.069±0.050	1.079±0.617	0.065±0.040
t	0.345	0.762**	0.224	0.667**
p	0.062	0.001	0.235	0.001

The data are mean±SD. **p<0.01. Ss, peak systolic strain; Sd, peak diastolic strain; SRs, peak systolic strain rate; SRd, peak diastolic strain rate.

Table V. Correlation of elasticity indexes between the long-axis and short-axis section of the anterior radial artery during systolic and diastolic periods.

Part	Ss/%	SRs/(1/s)	Sd/%	SRd/(1/s)
Long-axis section	-2.350±1.401	-0.142±0.115	1.950±1.386	0.137±0.080
Short-axis section	-1.214±0.647	-0.064±0.040	0.854±0.707	0.063±0.054
r	-0.005	0.314	0.260	0.382*
p	0.979	0.091	0.165	0.037

The data are mean±SD. *p<0.05. Ss, peak systolic strain; Sd, peak diastolic strain; SRs, peak systolic strain rate; SRd, peak diastolic strain rate.

Table VI. Correlation of elasticity indexes between the long-axis and short-axis section of the posterior radial artery during systolic and diastolic periods.

Part	Ss/%	SRs/(1/s)	Sd/%	SRd/(1/s)
Long-axis section	-2.032±1.415	-0.133±0.101	2.075±1.372	0.134±0.103
Short-axis section	-1.112±0.762	-0.069±0.050	1.079±0.617	0.065±0.040
r	0.075	0.185	0.244	0.166
p	0.692	0.328	0.194	0.381

The data are mean±SD. Ss, peak systolic strain; Sd, peak diastolic strain; SRs, peak systolic strain rate; SRd, peak diastolic strain rate.

plaque and arterial stenosis, which are associated with significant changes in hemodynamics. These subclinical changes are challenging to detect using conventional imaging techniques [6]. Previously, pulse wave velocity was considered the "gold standard" for evaluating overall arterial wall elasticity. However, this technique had limitations as it could not detect subtle changes in arterial elasticity and was susceptible to interference from factors such as blood pressure and heart rate [7]. In recent years, the application of VVI technology in the vascular field has gained significant attention. VVI is an innovative ultrasound technology that utilizes speckle tracking to assess tissue deformation. By using parameters like S and SR [8], VVI technology evaluates the biomechanical characteristics of blood vessels. This technology can detect changes in the structure and function of blood vessels before morphological changes occur, allowing for quantitative evaluation of vessel elasticity [9]. Notably, VVI technology demonstrates good repeatability [10]. Therefore, VVI technology offers more advantages than conventional ultrasound in quantitatively evaluating vessel wall function. Its ability to detect reductions in both systolic and diastolic function of vessel walls before irreversible decompensation changes occur provides a foundation for the evaluation and prevention of clinical vascular diseases, as well as reducing and delaying complications [11].

In recent years, there has been increasing interest in studying the elastic function of the carotid artery, which can reflect the systolic and diastolic functions of large arteries. However, it does not provide a comprehensive representation of the vascular state of medium muscular arteries. The radial artery, classified as a medium muscular artery, indirectly reflects the degree of hardening in the walls of cardiovascular and cerebrovascular vessels. It is a key vessel involved in essential hypertension, the preferred pathway for Arteriovenous fistula in ESRD patients, the bridging vessel for coronary artery bypass grafting, and a critical predictor of cardiovascular diseases in ESRD patients [12-14]. Research has shown that changes in the elastic function of the radial artery occur earlier than those in the carotid artery in patients with chronic kidney disease. Therefore, it is crucial to assess the elastic function of the radial artery. In some studies which have fewer anatomical branches compared to the carotid artery and other elastic arteries, it is less susceptible to factors such as cardiac contraction and blood flow impact, making it a more sensitive site for evaluating vascular elasticity function in ESRD patients. To date, there have been no reports on the application of VVI technology to assess the elastic function of the radial artery wall. In this study, we conducted a preliminary exploration of radial artery wall motion in long-axis and short-axis sections using the VVI technique. We aim to further develop the application of the VVI technique to evaluate wall systolic and diastolic motion and elasticity function in different sections of the radial artery.

The results of the present study demonstrate that there were no significant differences in the parameters of Ss, SRs, Sd, and SRd between the anterior and posterior walls in both long-axis and short-axis sections. This finding is consistent with the results of previous studies conducted by Gao et al [15] on carotid arteries. These findings suggest that the wall motion of the anterior and posterior walls exhibit synchronous deformation throughout the cardiac cycle when the radial artery is not

affected by disease. Additionally, no significant differences in local wall elasticity were observed. In the long-axis section, there were significantly positive correlations between Ss, SRs, and SRd of both the anterior and posterior walls. Similarly, Sd showed a positive correlation. In the short-axis section, there were significantly positive correlations between SRs and SRd of both the anterior and posterior walls. This suggests that SR may be a more sensitive parameter than S in assessing the early elastic function of the radial artery, supporting the conclusion of Pellerin et al [16] that SR is a more sensitive indicator in evaluating cardiac function. Moreover, Au et al [17] indicated that diastolic VVI parameter values may serve as a more direct and sensitive indicator for expressing the mechanical characteristics of the arterial wall. In this study, we observed a positive correlation between the SRd of the long-axis and short-axis sections of the radial artery's anterior wall. This finding aligns with the results reported by Au et al [17], supporting the notion that the diastolic period may serve as a better indicator for capturing early-stage changes in the radial artery's elastic function. Svedlund et al [18] noted that longitudinal motion indicators derived from long-axis sections might be more effective in reflecting early vascular wall remodeling and the effects of drug treatments compared to motion indicators obtained from short-axis sections. Moreover, the long-axis tracing range could be wider, potentially yielding more precise results. Our study further found that the correlation between the anterior and posterior walls of the long-axis section exhibited higher sensitivity compared to that of the short-axis section. There were no correlations between VVI parameters such as anterior Ss, Sd, SRs, posterior Ss, Sd, SRs, and SRd between the long-axis and short-axis sections, consistent with the findings reported by Svedlund et al [18]. This finding suggests that the long-axis and short-axis sections cannot be used interchangeably. VVI parameters in the long-axis section may be more sensitive in detecting early changes in wall elastic function in the study of the radial artery. Taken together, longitudinal SRd in the long-axis section may serve as a highly sensitive and accurate parameter for assessing changes in wall elastic function during the occurrence of radial artery lesions. The correlation of the parameters between the long-axis and short-axis sections was less than ideal in this study. This may be attributed to factors such as the thin wall of the radial artery and the subtle motion amplitude, which are often challenging to trace. Additionally, it may be related to the small sample size. Therefore, the experimental results have certain limitations.

In summary, the evaluation of radial artery wall motion using VVI technology in both long-axis and short-axis sections demonstrates specific feasibility. This method allows for the assessment of the motion characteristics of the radial artery wall, provision of structural and mechanical parameters of local blood vessels, and delivery of accurate preoperative information for clinical arteriovenous fistula and coronary artery bypass grafting. The evaluation of radial artery elasticity using VVI technology may offer a new approach to detecting early changes in wall systolic and diastolic motion. Moreover, due to its non-invasive nature and ability to be repeated, it is expected to serve as a follow-up examination and routine screening tool for patients. This will assist clinicians in detecting early-stage changes in arterial elasticity related to various diseases, facilitating timely interventions to mitigate the risk of vascular lesions. In the future, we will conduct further studies with enlarged sample sizes to provide a more reliable basis for analyzing radial artery wall motion.

Conclusions

VVI technology is feasible to quantitatively study the systolic and diastolic motion and elastic function of the radial artery in different sections. The elastic function of the radial artery is digitized and accurate, which provides a basis for clinical discovery and treatment, and reduces the occurrence of cardiovascular adverse events.

Conflict of interest: none

References

1. Yang WI, Shim CY, Bang WD, et al. Asynchronous arterial systolic expansion as a marker of vascular aging: assessment of the carotid artery with velocity vector imaging. J Hypertens 2011;29:2404-2412.
2. Jin CX, Tian J, Yang HH, He Y. A preliminary study of changes in carotid artery elasticity in type 2 diabetes mellitus. Clin Physiol Funct Imaging 2023;43:181-191.
3. Guérin AP, London GM, Marchais SJ, Metivier F. Arterial stiffening and vascular calcifications in end-stage renal disease. Nephrol Dial Transplant 2000;15:1014-1021.
4. Shan A, Zhou C, He Y, Feng W, Chen G, Zhong G. Expression of both matrix metalloproteinase-2 and its tissue inhibitor-2 in tunica media of radial artery in uremic patients. Ren Fail 2013;35:37-42.
5. Barr LC, Herr JE, Hétu MF, Smith GN, Johri AM. Increased carotid artery stiffness after preeclampsia in a cross-sectional study of postpartum women. Physiol Rep 2022;10:e15276.
6. Favreau JT, Liu C, Yu P, et al. Acute reductions in mechanical wall strain precede the formation of intimal hyperplasia in a murine model of arterial occlusive disease. J Vasc Surg 2014;60:1340-1347.

7. Hu JL, Li X, Wang XM, et al. Comparison of Elastic Properties of Bilateral Carotid Arteries in Relation to Site of Acute Ischemic Stroke Using Velocity Vector Imaging. Chin Med J (Engl) 2015;128:2960-2963.
8. Yu L, Xu G, Zhou Q, Ouyang M, Gao L, Zeng S. Biomechanical properties of the ascending aorta in patients with arterial hypertension by velocity vector imaging. Int J Cardiovasc Imaging 2024;40:397-405.
9. Saris AECM, Hansen HHG, Fekkes S, Menssen J, Nillesen MM, de Korte CL. In Vivo Blood Velocity Vector Imaging Using Adaptive Velocity Compounding in the Carotid Artery Bifurcation. Ultrasound Med Biol 2019;45:1691-1707.
10. Jin Y, Gao Y, Hou R, Cong S. Evaluation of left ventricular myocardial movement in rats by velocity vector imaging. PLoS One 2020;15:e0239869.
11. Cho IJ, Shim CY, Yang WI, et al. Assessment of mechanical properties of common carotid artery in Takayasu's arteritis using velocity vector imaging. Circ J 2010;74:1465-1470.
12. Bai Y, Zhang J, Xu J, Cui L, Zhang H, Zhang S. Alteration of type I collagen in the radial artery of patients with end-stage renal disease. Am J Med Sci 2015;349:292-297.
13. Blacher J, London GM, Safar ME, Mourad JJ. Influence of age and end-stage renal disease on the stiffness of carotid wall material in hypertension. J Hypertens 1999;17:237-244.
14. Georgiadis GS, Georgakarakos EI, Antoniou GA, et al. Correlation of pre-existing radial artery macrocalcifications with late patency of primary radiocephalic fistulas in diabetic hemodialysis patients. J Vasc Surg; 2014;60:462-470.
15. Gao J, Lee J, Phan A, Fowlkes JB. Velocity Vector Imaging to Assess Longitudinal Wall Motion of Adult Carotid Arteries. J Ultrasound Med 2021;40:1195-1207.
16. Pellerin D, Sharma R, Elliott P, Veyrat C. Tissue Doppler, strain, and strain rate echocardiography for the assessment of left and right systolic ventricular function. Heart 2003;89 Suppl 3:iii9-iii17.
17. Au JS, Valentino SE, McPhee PG, MacDonald MJ. Diastolic Carotid Artery Longitudinal Wall Motion Is Sensitive to Both Aging and Coronary Artery Disease Status Independent of Arterial Stiffness. Ultrasound Med Biol 2017;43:1906-1918.
18. Svedlund S, Gan LM. Longitudinal wall motion of the common carotid artery can be assessed by velocity vector imaging. Clin Physiol Funct Imaging 2011;31:32-38.