*Review*

*Med Ultrason 2023, Vol. 25, no. 3, 325-329*
**DOI:** 10.11152/mu-4060

# Sono-palpation and sono-Tinel in musculoskeletal ultrasound examination: use all "sono-senses". A systematic review

**Carmelo Pirri[1], Nina Pirri[2], Carla Stecco[1], Veronica Macchi[1], Andrea Porzionato[1], Raffaele De Caro[1], Levent Özçakar[3]**

[1]Department of Neurosciences, Institute of Human Anatomy, University of Padova, Padua, Italy, [2]Department of Medicine-DIMED, School of Radiology, Radiology Institute, University of Padua, Padova, Italy, [3]Department of Physical and Rehabilitation Medicine, Hacettepe University Medical School, Ankara, Turkey

**Abstract**

Flexibility and dynamic perspective of ultrasound imaging allow for a targeted/focused examination, yielding extra findings. Sonopalpation – also referred as sono-Tinel for nerves – is one of those particular features of ultrasound examination whereby the ultrasound probe is actively 'manipulated'. It is paramount to ascertain the painful structure/pathology during the evaluation of a patient and it is not possible with other imaging techniques other than ultrasonography. In this aspect, the current review aims to provide an analysis of the literature regarding the use of sonopalpation for clinical and research purposes respectively.

**Keywords:** ultrasonography; probe; muscle; bone; pain

## Introduction

Obtaining accurate ultrasound (US) examination findings is one of the most basic and important skills for medical doctors [1]. US examination allows for non-invasive, real-time, comprehensive and patient/physician-friendly evaluation – compared with other diagnostic imaging techniques [2]. For instance, during interactive imaging, compression of the probe (for localizing the painful/symptomatic region) is commonly referred as sonopalpation [1-3]. It is imperative for an accurate diagnosis as well as for prompting treatment [2,3].

Concerning other clinical scenarios, sonopalpation is used to help in the diagnosis of head and neck masses [4,5]. Similarly, Faust et al [6] demonstrated that it can help physicians to localize pain related to particular organs e.g. in cases of suspected acute pyelonephritis lacking classical features. Another well-known application in medicine is "the sonographic Murphy sign" that has 93.6% of specificity and 63% sensitivity for the diagnosis of acute cholecystitis [7]. Other diverse applications in clinical context have been described, including pelvic inflammatory disease, appendicitis and breast cancer [8-11]. Lichtenstein [12] showed the use of point-of-care US and sonopalpation to identify the source in patients with sepsis. Notably, the term sonopalpation is sometimes different when compared to its use in the musculoskeletal system. Patel et al [13] reported that the integration of US imaging into clinical examination (using 'sonopalpation') provides a useful method to diagnose sialolithiasis i.e. with the involvement of the non-scanning hand to palpate and move tissues toward the transducer during real-time scanning.

Likewise, the use of sonopalpation (sono-Tinel for nerves) in neuromusculoskeletal US is important as in other types of sonographic examinations [1-3]. Accordingly, in this review, we discuss the application of sonopalpation in different/painful clinical situations.

Received 05.02.2023 Accepted 22.04.2023
Med Ultrason
2023, Vol. 25, No 3, 325-329
Corresponding author: Carmelo Pirri, MD, PT
Department of Neurosciences, Institute of Human Anatomy, University of Padova, 35121 Padova, Italy
E-mail: carmelop87@hotmail.it

## Materials and methods

A substantial literature search was carried out to review the literature from 1960 up to January 2023. Three electronic databases, i.e. PubMed, Web of Science and Google Scholar were used to identify all relevant English papers without any category restriction. The MeSH keywords used were: "Sono-palpation", "Joint", "Tendon", "Ligament", "Muscle", "Fascia", "Peripheral nerve", "Bursa", "Meniscus", "Sono-Tinel". The search strategy was the following: ("Sono-palpation") OR ("Sono-palpation" AND "Joint") OR ("Sono-palpation" AND "Tendon") OR ("Sono-palpation" AND "ligament") OR ("Sono-palpation" AND "Skeletal Muscle") OR ("Sono-palpation" AND "Fascia") OR ("Sono-palpation" AND "Peripheral Nerve") OR ("Sono-Tinel AND Peripheral Nerve") OR ("Sono-palpation" AND "Bursa") OR ("Sono-palpation" AND "Meniscus"). The search was extended through the reference lists of the chosen texts. Relevant secondary references were also captured. Different pathologies/conditions were found in which the use of sonopalpation was fundamental (Table I).

Two reviewers (CP and NP) independently selected the papers by reading their titles and abstracts. A third reviewer (LÖ) finalized the selection in case of disagreement. After the selection, each paper was independently evaluated by the two authors and the following data were recorded. Any discrepancy was resolved by agreement among the authors. The study flowchart is shown in figure 1.

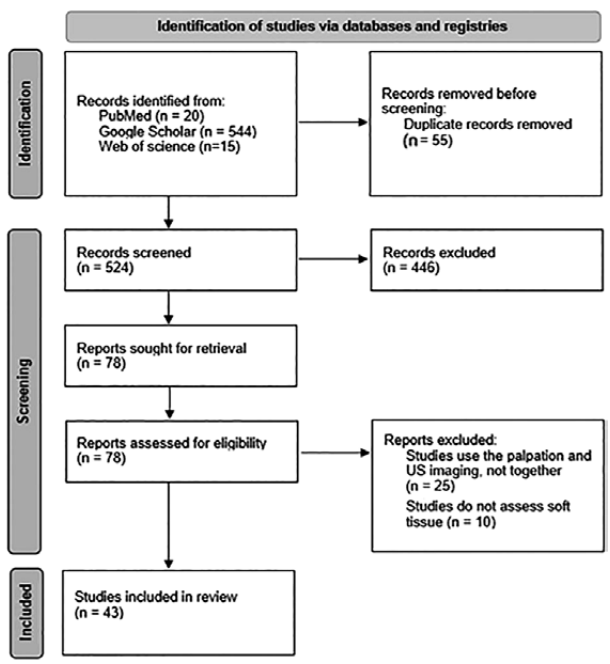


**Fig 1.** Study flow diagram.

Table I. Exemplary pathologies for the use of sonopalpation

| Tissue | Pathology |
|---|---|
| Skin/subcutaneous tissue | Cyst, lipoma |
| Fascia | Fasciitis |
| Tendon and ligament | Sprain, (calcific) tendinopathy, enthesopathy |
| Bursa | Bursitis |
| Skeletal muscle | Strain, atrophy, myositis ossificans |
| Joint and capsule | Effusion/synovitis, adhesive capsulitis, loose body (osteochondritis dissecans) |
| Cartilage | Degeneration, meniscopathy |
| Peripheral nerve | Entrapment |
| Bony/periosteum | Erosion and fracture |

## Results

### *Skin/subcutaneous tissue*

Anderson et al [14] reported that in 38% of cases, foreign bodies can be overlooked at the initial clinical investigation, whereas sonopalpation can help physicians to track down the area/position of deeply located fragments. Sonopalpation was fundamental in precisely locating the exact cause of pain, due to cyst and lipoma as well [15-17]. In addition, sonopalpation also provides insight into better understanding their content (fluid or semi-solid).

### *Fascia*

Pirri et al [15,17-20] showed that fascial sonopalpation can track down fascial involvement in numerous musculoskeletal dysfunctions and that pain management could be tailored accordingly. For instance, persistent scar pain associated with healed surgical incisions after trauma is potentially a debilitating type of fascial pain which can be assessed/detected with sonopalpation [15]. Again, Chang et al [21] reported that sonopalpation was crucial in the differential diagnosis between sesamoid bone avulsion and plantar fasciitis.

### *Tendon/ligament/bursa*

Tendon abnormalities identified with US examination include tendinosis (appearing hypoechoic and possibly swollen), partial or interstitial tears (appearing as anechoic clefts or partial fiber discontinuity), and complete tears (full-thickness tendon discontinuity) [22]. Inspection and sonopalpation of the affected tendon are needed to rule out local edema and ecchymosis, revealing tenderness and mass effect by swelling. In a case of proximal lateral gastrocnemius tendon sprain, Chang et al [23] reported that sonopalpation helped to detect the lesion. Norbury et al [24] showed a case of palmaris longus tendinopathy diagnosed by tenderness upon sonopalpation when

compared to the contralateral side. Of note, enthesopathy and spurs with tendon inflammation can also/easily be palpated by the US probe [25].

The use/indications for ligaments are quite similar to those of tendons [26,27]. Concerning bursae, they can readily be evaluated by US examination – also to understand the displacement of its content and their connections [28-30].

***Skeletal Muscle***

US examination is a validated tool for assessing muscle quantity as well as for the evaluation of muscle injuries [31-33]. With sonopalpation, it is possible to localize the pain and a tear in minor injuries and, in moderate lesions, sonopalpation is also informative with regards to the defect size and presence of hematoma. In subtotal/total muscle tears, it also helps to characterize the functional impairment, muscle retraction and area of severe pain [34,35]. Dynamic imaging with sonopalpation is again essential for the evaluation of muscle hernias [36].

***Nerve***

Ultrasonographic Tinel sign refers to the compression at the site of the nerve lesion whereby enlarged (and in case of neuromas, disorganized) nerves are commonplace [37,38]. Sono-Tinel sign can also be used to guide biopsy when necessary [38].

***Joint/Bone/Meniscus***

The demonstration of intra-articular effusion is the most common and main purpose of sonopalpation during the US examination [26,27]. Moreover, US also permits the differentiation between effusion and synovial hypertrophy which might be paramount for several inflammatory conditions [39]. While not being definitive, it might also be possible to distinguish other fluid accumulations of hematogenic or infectious origins. Moreover, intra-articular loose bodies can also be detected/mobilized in joint recesses by sonopalpation – especially for reproducing the painful mechanical conflict [40-43].

Sonopalpation can be effectively used to assess tiny lesions of the bony cortex whereby routine radiographs could be noncontributory [26,27,44]. Concerning menisci, especially their (radial) tears extending towards the outer parts of the joints can be imaged/assessed by probe/limb/joint movements [45].

## Discussion

To the best knowledge of the authors, this is a unique review of 43 studies on the use of sonopalpation during neuromusculoskeletal US. Serving as a combination of physical and US examination, its concept perfectly matches with the philosophy of US i.e. being dynamic/interactive and patient/physician friendly. This issue seems to have been reflected to the pertinent literature as well.

Several studies have confirmed that sonopalpation is often used as part of the US examination in patients with soft tissue injuries. The majority of the reviewed papers reported the challenges in making sonopalpation a staple of US examination [14-45]. Herein, it is noteworthy that US examination must be individualized for each/every patient in light of the clinical symptoms/signs/findings. Indeed, the sonographer has the chance/ability to use sonopalpation and receive real-time immediate feedback from the patient [1]. For a clinician, when used effectively, this feature can be second to none for prompt patient evaluation and treatment planning [3]. Joints, ligaments, tendons, fasciae, bursae, muscles, nerves and subcutaneous tissue can all be assessed by this dynamic maneuver with high sensitivity to explore pain [33,37,44].

As US technology is improving, palpation skills using the probe are expected to increase in the future. Accordingly, a systematic approach regarding various landmarks might be necessary to add in US training [45]. Moreover, again with the developing US technology (e.g. artificial intelligence), it would not be unreasonable to consider alternative 'palpation' techniques that are currently absent [44,46,47].

To the best of our knowledge, this is the first review about sonopalpation for the evaluation of muscle-skeletal soft tissues. Our review suggests that sonopalpation is superior to US or physical examination alone and is very helpful in the diagnosis and management of various muscle-skeletal soft tissues diseases. This is a commentary that may have excluded other muscle-skeletal soft tissues. Further studies should be carried out to clearly define the role of sonopalpation in diverse clinical conditions.

As a limitation, despite the fact that we systematically conducted a literature search to reduce selection bias, some studies may have been inevitably omitted. Future prospective high-quality studies on the use of sonopalpation during neuromusculoskeletal US examination are definitely welcome.

## Conclusions

The flexibility and dynamic capability of US imaging allows for a targeted US examination, which can be effortlessly and individually adjusted/manipulated for each person. Sonopalpation by applying probe pressure under real-time visualization can reveal important information regarding the composition and extent of the underlying neuromusculoskeletal pathology. We eagerly anticipate further research as technology continues to evolve and

the clinical usefulness of ultrasound imaging/examination increases.

**Acknowledgements:** We acknowledge the Institute of Human Anatomy of University of Padova.

**Conflict of interest:** none

## References

1. Kitagawa T, Aoki Y, Sugimoto H, Ozaki N. Randomised controlled trial for evaluation of an ultrasound-guided palpation intervention for palpation skill training. Sci Rep 2022;;12:1189.
2. Özçakar L, Çarlı AB, Tok F, Tekin L, Akkaya N, Kara M. The utility of musculoskeletal ultrasound in rehabilitation settings. Am J Phys Med Rehabil 2013;92:805–817.
3. Riccabona M. Modern pediatric ultrasound: potential applications and clinical significance: a review. Clin Imaging 2006;30:77–86.
4. Baatenburg de Jong RJ, Rongen RJ, Lameris JS, Harthoorn M, Verwoerd CD, Knegt P. Metastatic neck disease. Palpation vs US examination. Arch Otolaryngol Head Neck Surg 1989;115:689-690.
5. Gritzmann N, Grasl MC, Helmer M, Steiner E. Invasion of the carotid artery and jugular vein by lymph node metastases: detection with sonography. AJR Am J Roentgenol 1990;154:411-414.
6. Faust JS, Tsung JW. Eliciting renal tenderness by sonopalpation in diagnosing acute pyelonephritis. Crit Ultrasound J 2017;9:1.
7. Ralls PW, Halls J, Lapin SA, Quinn MF, Morris UL, Boswell W. Prospective evaluation of the sonographic Murphy sign in suspected acute cholecystitis. J Clin Ultrasound 1982;10:113–115.
8. Tayal VS, Crean CA, Norton HJ, Schulz CJ, Bacalis KN, Bliss S. Prospective comparative trial of endovaginal sonographic bimanual examination versus traditional digital bimanual examination in nonpregnant women with lower abdominal pain with regard to body mass index classification. J Ultrasound Med 2008;27:1171–1177.
9. Lewiss RE, Saul T, Goldflam K. Sonographic cervical motion tenderness a sign found in a patient with pelvic inflammatory disease. Crit Ultrasound J 2012;4:20.
10. Elikashvili I, Tay ET, Tsung JW. The effect of point-of-care ultrasonography on emergency department length of stay and computed tomography utilization in children with suspected appendicitis. Acad Emeg Med 2014;21:163–170.
11. Zuna I, Delorme S, Huber S, et al. A multicenter study of diagnostic criteria in ultrasound mammography. Statistical pitfalls and ways out of the data jungle. Radiologe 1998;38:355–363.
12. Lichtenstein DA. Point-of-care ultrasound: infection control in the intensive care unit. Crit Care Med 2007;35(5 Suppl):S262–S267.
13. Patel NJ, Hashemi S, Joshi AS. Sonopalpation: a novel application of ultrasound for detection of submandibular calculi. Otolaryngol Head Neck Surg 2014151:770-775.
14. Anderson MA, Newmeyer WL 3rd, Kilgore ES Jr. Diagnosis and treatment of retained foreign bodies in the hand. Am J Surg 1982;144:63–67.
15. Pirri C, Stecco A, Fede C, De Caro R, Stecco C, Özçakar L. Ultrasound imaging of a scar on the knee: Sonopalpation for fascia and subcutaneous tissues. Eur J Transl Myol 2020;;30:8909.
16. Pirri C, Stecco C, Pirri N, De Caro R, Özçakar L. Ultrasound examination avoids tunnel vision: diagnosing a simple/painful (epi)dermal cyst. Med Ultrason 2022;24:377-378.
17. Pirri C, Stecco C, De Caro R, Foti C, Özçakar L. Radiating Upper Limb Pain Due to a Large Subcutaneous Lipoma: Fascial Sono-Palpation. Pain Med 2020; 21:3721-3723.
18. Pirri C, Stecco C, Fede C, Macchi V, Özçakar L. Ultrasound Imaging of the Fascial Layers: You See (Only) What You Know. J Ultrasound Med 2020; 39:827-828.
19. Pirri C, Pirri N, Porzionato A, Boscolo-Berto R, De Caro R, Stecco C. Inter- and Intra-Rater Reliability of Ultrasound Measurements of Superficial and Deep Fasciae Thickness in Upper Limb. Diagnostics (Basel) 2022;12:2195.
20. Pirri C, Ricci V, Stecco C, Özçakar L. Clinical and Ultrasound Examination of the Thoracolumbar Fascia: The Hands and the Probe Together. Am J Phys Med Rehabil 2021;100:e157-e158.
21. Chang KV; Hung CY, Özçakar L. Medial sesamoid bone avulsion but not plantar fasciitis: ultrasonographic diagnosis using sonopalpation. Pain Physician 2015;18:E87-E88.
22. Smith J, Sayeed YA, Finnoff JT, Levy BA, Martinoli C. The bifurcating distal biceps femoris tendon: potential pitfall in musculoskeletal sonography. J Ultrasound Med 2011;30:1162–1166.
23. Chang KV, Wu WT, Özçakar L. An Overlooked Cause of Posterior Knee Pain: Ultrasound Imaging and Guided Injection for Proximal Lateral Gastrocnemius Tendon Sprain. Med Ultrason 2020;22:377-378.
24. Norbury JW, Morrison EJ. Palmaris Longus Tendinopathy Diagnosed With Ultrasound: A Case Report. PM R 2019;11:433-435.
25. Pirri C, Stecco C, Pirri N, De Caro R, Özçakar L. Imaging the Enthesopathy and Manipulating the Fascia: Ultrasound is the "Sous Chef". Eur J Rheumatol 2023;10:45-46.
26. Özgül B, Starbuck C, Polat MG, Abdeen R, Nester C. Inter and intra-examiner reliability of musculoskeletal ultrasound scanning of Anterior Talofibular Ligament and ankle muscles. J Ultrasound 2023;26:137-146.
27. Bodor M, Fullerton B. Ultrasonography of the hand, wrist, and elbow. Phys Med Rehabil Clin N Am 2010;21:509-531.
28. Chen B, Rispoli L, Stitik T, Leong M. Successful Treatment of Gluteal Pain from Obturator Internus Tendinitis and Bursitis with Ultrasound-Guided Injection. Am J Phys Med Rehabil 2017;96:e181-e184.
29. Galletti L, Ricci V, Andreoli E, Galletti S. Treatment of a calcific bursitis of the medial collateral ligament: a rare cause of painful knee. J Ultrasound 2019;22:471-476.
30. Viegas FC, Aguiar RO, Gasparetto E, et al. Deep and superficial infrapatellar bursae: cadaveric investigation of re-

gional anatomy using magnetic resonance after ultrasound-guided bursography. Skeletal Radiol 2007;36:41–46.
31. Nijholt W, Scafoglieri A, Jager-Wittenaar H, Hobbelen JSM, van der Schans CP. The reliability and validity of ultrasound to quantify muscles in older adults: a systematic review. J Cachexia Sarcopenia Muscle 2017;8:702–712.
32. Wang JC, Wu WT, Chang KV, et al. Ultrasound Imaging for the Diagnosis and Evaluation of Sarcopenia: An Umbrella Review. Life (Basel) 2021;12:9.
33. Forlizzi JM, Ward M, Whalen J, Wuerz TH, Gill TJ. Core Muscle Injury: Evaluation and Treatment in the Athlete. Am J Sports Med 2023;51:1087-1095.
34. Mueller-Wohlfahrt HW, Haensel L, Mithoefer K, et al. Terminology and classification of muscle injuries in sport: The Munich consensus statement. Br J Sports Med 2013;47:342–350.
35. Ekstrand J, Askling C, Magnusson H, Mithoefer K. Return to play after thigh muscle injury in elite football players: Implementation and validation of the Munich muscle injury classification. Br J Sports Med 2013;47:769–774.
36. Güvener O, Özçakar L. Dynamic and interactive ultrasound examination for muscle hernia: 'Here it comes again!' Turk J Phys Med Rehabil 2022;68:437-438.
37. Chipman JN, Mott RT, Stanton CA, Cartwright MS. Ultrasonographic Tinel sign. Muscle Nerve 2009;40:1033-1035.
38. Lucchetta M, Briani C, Liotta GA, Martinoli C, Coraci D, Padua L. Ultrasonographic Tinel sign: comment. Muscle Nerve 2010;41:570-571.
39. Özçakar L, Ricci V, Mezian K, Pirri C. A New and Dedicated Video Gallery: EURO-MUSCULUS/USPRM Protocols for Dynamic Ultrasound Examination of the Joints. Am J Phys Med Rehabil 2022;101:201-202.
40. Jacobson JA, Ruangchaijatuporn T, Khoury V, Magerkurth O. Ultrasound of the Knee: Common Pathology Excluding Extensor Mechanism. Semin Musculoskelet Radiol 2017;21:102-112.
41. Roberts D, Miller TT, Erlanger SM. Sonographic appearance of primary synovial chondromatosis of the knee. J Ultrasound Med 2004;23:707–709.
42. Ricci V, Özçakar L, Galletti L, Domenico C, Galletti S. Ultrasound-Guided Treatment of Extrusive Medial Meniscopathy: A 3-Step Protocol. J Ultrasound Med 2020;39:805-810.
43. Serrano S, Ferreira JB, Özçakar L. When "Sono-Palpation" Becomes "Sono-Explosion": The Baker's Cyst Report. Am J Phys Med Rehabil 2020;99:e125.
44. Cocco G, Ricci V, Villani M, et al. Ultrasound imaging of bone fractures. Insights Imaging 2022;13:189.
45. Pirri C, Stecco C, Güvener O, et al. EURO-MUSCULUS/USPRM Dynamic Ultrasound Protocols for Knee. Am J Phys Med Rehabil 2023;102:e67-e72.
46. Bitterman J, Lew HL, Kirshblum S, Enam N, Pierce D, Ma RT. Design and Implementation of a Musculoskeletal Ultrasound Curriculum for Physical Medicine and Rehabilitation Residents: Pilot Data on Improvement of Palpation Accuracy in Physical Examination. Am J Phys Med Rehabil 2020;99:1177-1183.
47. Mieritz RM, Kawchuk GN. The accuracy of locating lumbar vertebrae when using palpation versus ultrasonography. J Manipulative Physiol Ther 2016;39;387–392.