*Case report*

*Med Ultrason 2017, Vol. 19, no. 3, 333-335*
DOI: 10.11152/mu-1085

# Tuberculous appendicitis. A case report

**Bogdan Augustin Chiș[1], Vlad Dudric[2], Daniela Fodor[1]**

[1]2nd Internal Medicine Department, [2]5th Surgical Department, "Iuliu Hatieganu" University of Medicine and Pharmacy, Cluj-Napoca, Romania

**Abstract**

Double localization of tuberculosis is a rare finding among immunocompetent patients. Intestinal tuberculosis is a rare condition and its diagnosis remains a challenge to the physician. We present the case of a 21 year old male patient with intestinal tuberculosis in which the first manifestation was an acute appendicitis. Ultrasound findings were an abscessed appendicular mass. The surgical intervention found a granulomatous aspect of the peritoneum and total necrosis of the appendix. Histopathological examination confirmed the diagnosis and the pulmonary radiography detected the concomitant pulmonary tuberculosis.

**Keywords**: tuberculosis; appendicitis; ultrasonography

## Introduction

Tuberculosis (TB) remains a major global health problem, with high morbidity and mortality, especially in underdeveloped countries [1,2]. Out of the total TB cases, only 10-12% cases are extrapulmonary TB [3]. The ileocecal region is affected in 64-75% of cases of gastrointestinal TB, followed by the jejunum, and colon [4,5], mainly in young adults with a slight female predominance [6]. There are no specific clinical and radiological findings, so the final diagnosis is possible in the majority of cases only after histopathological examination [4]. TB with double localization is a rare condition, found mainly in patients with low immunity status or pregnancy, and respiratory symptomatology is the most important.

We report the case of a young male with TB appendicitis as a rare cause of abdominal pain.

## Case report

A 21 year old male patient was admitted in the emergency room with constant and moderate lower abdominal pain, especially in the right iliac fossa, diarrhea (3-4 stools/day) and fever (up to 38°C). The symptoms started two months prior presentation when the symptomatology was interpreted by the general practitioner as enterocolitis and was treated with antibiotics (fluoroquinolones), but no amelioration was obtained. At presentation a moderate painful abdominal mass in the lower right quadrant was palpated but without a peritoneal reaction. An elevated white cell count with neutrophila was found, but no other lab alterations.

Ultrasonography performed with a 3.5 MHz transducer on Esaote Mylab 50 XVision found a 4 cm isoechoic mass with a hypoechoic center in the lower right abdominal quadrant, at the end of an intestinal-like structure, with inflamed surrounding ileum and jejunum. Slightly hypervascularisation of the affected intestinal wall on Doppler examination and minimal ascites were also noted (fig 1).

As the pain became more intense, and an acute diverticulitis could not be excluded, no endoscopic investigations were performed. Computed tomography showed in hypogastrium towards the right inguinal fossa a mass with high contrast agent capture and a liquid center, with a small lateral cystic-like zone. An abscess was concluded, which could involve the appendicular area (fig 2).

An acute appendicitis with appendicular block was concluded and antibiotics were prescribed. (ceftazidime 3 grams and metronidazole 1 gram daily). The white cell count continued to grow (12.610/µl), with low lympo-

Received 22.02.2017 Accepted 16.04.2017
Med Ultrason
2017, Vol. 19, No 3, 333-335
Corresponding author: Bogdan Augustin Chis, MD, PhD
2-4 Clinicilor street
400006, Cluj Napoca, Romania
Phone:(+40)740-047253
E-mail: bogdan_a_chis@yahoo.com

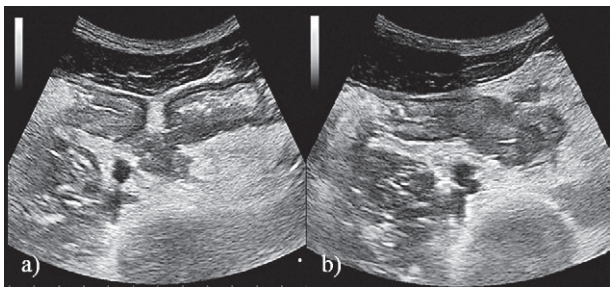


**Fig 1.** Ultrasonography examination: a) transversal section of the lower right quadrant: inhomogeneous masscontaining hypoechoic areas and thickened intestinal wall; b) sagittal scan of the right inguinal fossa showing a thick, inflamed intestinal wall.

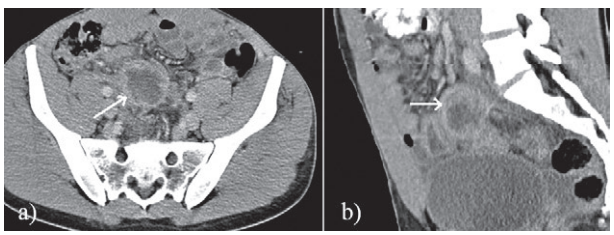


**Fig 2.** Computed tomography: transversal section in the hypogastrium showing the abscess (a) and thickened intestinal walls in a coronal section (b).

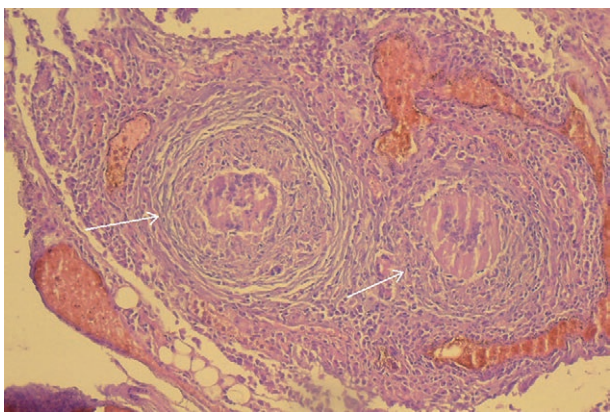

**Fig 3.** Hematoxylin-eosin stain showing granulomatous infiltrations.

cytes (1.640/µl) and high neutrophils (9.220/µl). Also, liver transaminases elevated, a prolonged prothrombin time (19.9 seconds), and a high inflammatory status (erythrocyte sedimentation rate=50 mm/h, high sensitive C-reactive protein=12 mg/L) were noted in laboratory tests. As biological and clinical status did not improve, appendectomy was decided. The surgical intervention found the peritoneum, the entire abdominal serosa and the greater omentum covered in miliary like lesions. In the right iliac fossa, an inflammatory block was found in which the appendix, cecum, sigmoid, and the last ileal ansa were caught. At the extracorporeal dissection, a small quantity of pus was revealed and the appendix with total necrosis was observed.

Histopathological analysis (incuding the peritoneal miliary lesions) showed granulomatous inflammation with caseous necrosis and ascites and pus samples were positive for bacillary infection (fig 3).

Pulmonary radiography found specific small lesions in the right upper lobe and the sputum culture exam was positive for Mycobacterium Tuberculosis (the primary lesion). No alteration of the immunological status was found. The specific tuberculostatic treatment was started with normalization of the laboratory tests in two weeks and progressive improvement of the health status.

## Discussions

Our patient was a young immunocompetent male, with double localization of TB (pulmonary and intestinal). The appendicitis was the first manifestation, without any pulmonary symptomatology.

Intestinal TB represents 11-16% of extrapulmonary TB and can occur as a primary (bacillus ingestion) or a secondary infection, when the lung is first affected. The dissemination can be haematogenous, through the lymphatic channel or from the adjacent foci [7,8]. TB appendicitis is a rare condition (about 0.1-0.2% of all acute appendicitis) and has no specific symptoms [9,10]. Our patient had a subacute onset. Other published cases showed different types of onset of TB appendicitis, either acute, moreover with classical appendicitis signs [11], or subacute, the rarest, with appendiceal mass, often treated for acute gastroenteritis [12]. Most frequent symptoms cited are weight loss, weakness, lack of appetite, along with uncharacteristic abdominal pain, as our patient [13]. Anti-tuberculous treatment must be initiated early for a good outcome [14].

Double localization of TB occurs mainly in immunological impaired patients with important symptomatology (weight loss, hemoptysis, acute surgical abdomen). Unspecific findings in early abdominal TB include a hypoechogenic mural thickening of the ileal folds (6 to 10 mm) with hypervascularization at Doppler examination along with thickened mesentery (up to 45 mm, due to fat deposition) and lymph nodes (up to 30 mm, with hypoechoic center due to caseation necrosis), and low quantities of ascites. A non-compressible adynamic appendix with the loss of inner layers could be signs of acute appendicitis. If perforated, pericaecal fluid, loss of the echogenic submucosa or generalized adynamic ileus is observed. Hyperperistalsis of the affected area can rarely be observed [15-17]. In HIV patients, spleen involvement is common (hypoechoic lesions) [18]. All the removed ap-

pendixes should be histopathologically examined, as TB appendicitis can be established only after Ziehl-Neelsen or direct hematoxylin-eosin colorations [19].

Ultrasound diagnosis of TB appendicitis is very difficult and must always be correlated with clinical manifestations. Even if the first symptoms can mimic other diseases, TB should be considered in high TB prevalence areas until otherwise ruled out.

**References**


1. World Health Organization. Global Tuberculosis Report 2015. Geneva. Available at: http://www.who.int/tb/publications/global_report/en. Accessed at 21st of December 2016.
2. Spence DP, Hotchkiss J, Williams CS, Davies PD. Tuberculosis and poverty. BMJ 1993;307:759-761.
3. McGuinness FE. Tuberculosis of the gastrointestinal tract and peritoneum. In: McGuinness. Clinical imaging of non-pulmonary tuberculosis. Springer Berlin Heidelberg 2000:107-137.
4. Debi U, Ravisankar V, Prasad KK, Sinha SK, Sharma AK. Abdominal tuberculosis of the gastrointestinal tract: revisited. World J Gastroenterol 2014;20:14831-14840.
5. Kapoor VK. Abdominal tuberculosis. Indian J Gastroenterol 1998;17:141-147.
6. Bobrow ML, Friedman S. Tubercular appendicitis. Am J Surg 1956;91:389-393.
7. Horvath KD, Whelan RL. Intestinal tuberculosis: return of an old disease. Am J Gastroenterol 1998;93:692-696.
8. Alvares JF, Devarbhavi H, Makhija P, Rao S, Kottoor R. Clinical, colonoscopic, and histological profile of colonic tuberculosis in a tertiary hospital. Endoscopy 2005;37:351-356.
9. Tesfamariam Sengal A, Abdalla Mohamedani A, Hussein HH, Kamal A. The Role of PCR in Diagnosis of a Rare Appendicular Tuberculosis and Mini Literature Review. Case Rep Gastrointest Med 2016;2016:8356708.
10. Zaghlool DA, Hassan AA, Ahmed MA, Faidah HS. Incidental parasitic infections in surgically removed appendices: a retrospective analysis. J Egypt Soc Parasitol 2015;45:571-578.
11. Rabbani K, Narjis Y, Difaa A, Louzi A, Benelkhaiat R, Finech B. Tuberculous appendicitis. Saudi J Gastroenterol 2011;17:287-288.
12. Chong VH, Telisinghe PU, Yapp SK, Chong CF. Tuberculous appendix: a review of clinical presentations and outcomes. Singapore Med J 2011;52:90-93.
13. Uzunkoy A, Harma M, Harma M. Diagnosis of abdominal tuberculosis: experience from 11 cases and review of the literature. World J Gastroenterol 2004;10:3647-3649.
14. Alrajhi AA, Halim MA, al-Hokail A, Alrabiah F, al-Omran K. Corticosteroid treatment of peritoneal tuberculosis. Clin Infect Dis 1998;27:52-56.
15. Roccarina D, Garcovich M, Ainora ME, et al. Diagnosis of bowel diseases: The role of imaging and ultrasonography. World J Gastroenterol 2013;19:2144-2153.
16. Jain R, Sawhney S, Bhargava DK, Berry M. Diagnosis of abdominal tuberculosis: sonographic findings in patients with early disease. AJR Am J Roentgenol 1995;165:1391-1395.
17. Kuzmich S, Howlett DC, Andi A, Shah D, Kuzmich T. Transabdominal sonography in assessment of the bowel in adults. AJR Am J of Roentgenol 2009;192:197-212.
18. Agarwal D, Narayan S, Chakravarty J, Sundar S. Ultrasonography for diagnosis of abdominal tuberculosis in HIV infected people. Indian J Med Res 2010;132:77-80.
19. Limaiem F, Arfa N, Marsaoui L, Bouraoui S, Lahmar A, Mzabi S. Unexpected histopathological findings in appendectomy specimens: a retrospective study of 1627 cases. Indian J Surg 2015;77:1285-1290.