

## Comments and illustrations of the WFUMB CEUS liver guidelines: Rare focal liver lesions – non-infectious, non-neoplastic

**Kathleen Möller<sup>1</sup>, Bahar Stock<sup>2</sup>, André Ignee<sup>3</sup>, Ehsan Safai Zadeh<sup>4</sup>, Chiara De Molo<sup>5</sup>, Carla Serra<sup>5</sup>, Christian Jenssen<sup>6</sup>, Adrian Lim<sup>7</sup>, Christian Görg<sup>4</sup>, Yi Dong<sup>8</sup>, Christoph Klinger<sup>9</sup>, Claudio Tana<sup>10</sup>, Maria Franca Meloni<sup>11</sup>, Zeno Sparchez<sup>12</sup>, Giampiero Francica<sup>13</sup>, Klaus Dirks<sup>14</sup>, Alois Hollerweger<sup>15</sup>, Horst Kinkel<sup>16</sup>, Hans-Peter Weskott<sup>17</sup>, Nathally Espinosa Montagut<sup>18</sup>, David Srivastava<sup>2,19</sup>, Christoph F. Dietrich<sup>2</sup>**

<sup>1</sup>Medical Department I/Gastroenterology, SANA Hospital Lichtenberg, Berlin, Germany, <sup>2</sup>Department Allgemeine Innere Medizin, Kliniken Hirslanden, Beau Site, Salem und Permanence, Bern, Switzerland, <sup>3</sup>Medical Clinic, Department for Gastroenterology and Rheumatology, Klinikum Wuerzburg Mitte, Wuerzburg, Germany, <sup>4</sup>Interdisciplinary Center of Ultrasound Diagnostics, University Hospital Giessen and Marburg, Philipps University Marburg, Marburg, Germany, <sup>5</sup>Interventional, Diagnostic and Therapeutic Ultrasound Unit, Department of Medical and Surgical Sciences, IRCCS, Azienda Ospedaliero-Universitaria Sant'Orsola Malpighi Hospital, Bologna, Italy, <sup>6</sup>Medical Department, Krankenhaus Maerkisch-Oderland, Strausberg, Brandenburg Institute of Clinical Medicine at Medical University Brandenburg, Germany, <sup>7</sup>Imperial College London and Healthcare NHS Trust, London, UK, <sup>8</sup>Interdisciplinary Center of Ultrasound Diagnostics, University Hospital Giessen and Marburg, Philipps University Marburg, Marburg, Germany, <sup>9</sup>Department of Ultrasound, Xinhua Hospital Affiliated to Shanghai Jiaotong University School of Medicine, Shanghai, China, <sup>10</sup>Department of Internal Medicine 1, Klinikum Ludwigsburg, Ludwigsburg, Germany, <sup>11</sup>Geriatrics Clinic, University Hospital of Chieti, Chieti, Italy, <sup>12</sup>Department of Radiology, University of Wisconsin, Madison, Wisconsin, USA, Department of Interventional Ultrasound Casa di Cura Igea, Milano, Italy, <sup>13</sup>Department of Internal Medicine-Gastroenterology, University of Medicine and Pharmacy, Cluj-Napoca, Romania, <sup>14</sup>Interventional Ultrasound Unit, Pinetagrando, Hospital Castelvoturno (CE), Italy, <sup>15</sup>Reims-Murr-Klinikum, Winnenden, Germany, <sup>16</sup>Department of Radiology and Nuclear Medicine, Barmherzige Brüder Hospital Salzburg, Austria, <sup>17</sup>Medical Care Center RUR, Gastroenterology, Düren, Germany, <sup>18</sup>KRH Siloah Clinic, Hannover, Germany, <sup>19</sup>School of Medicine, Universidad de los Andes, Bogotá, Colombia, <sup>19</sup>Inselspital Bern, Hospital of the University of Bern, Switzerland

### Abstract

In this series of papers on comments and illustrations of the World Federation for Medicine and Biology (WFUMB) guidelines on contrast enhanced ultrasound (CEUS) the topics of non-infectious and non-neoplastic focal liver lesions (FLL) are discussed. Improved detection and characterization of common FLL are the main topics of these guidelines but detailed and illustrating information is missing. The focus in this paper is on non-infectious and non-neoplastic FLL and their appearance on B-mode, Doppler ultrasound and CEUS features. Knowledge of these data should help to raise awareness of these rarer findings, to think of these clinical pictures in the corresponding clinical situation, to interpret the ultrasound images correctly and thus to initiate the appropriate diagnostic and therapeutic steps in time.

**Keywords:** Inflammatory pseudotumor; solitary necrotic nodules; intrahepatic splenosis; intrahepatic endometriosis; CEUS

Received 06.02.2023 Accepted 07.05.2023

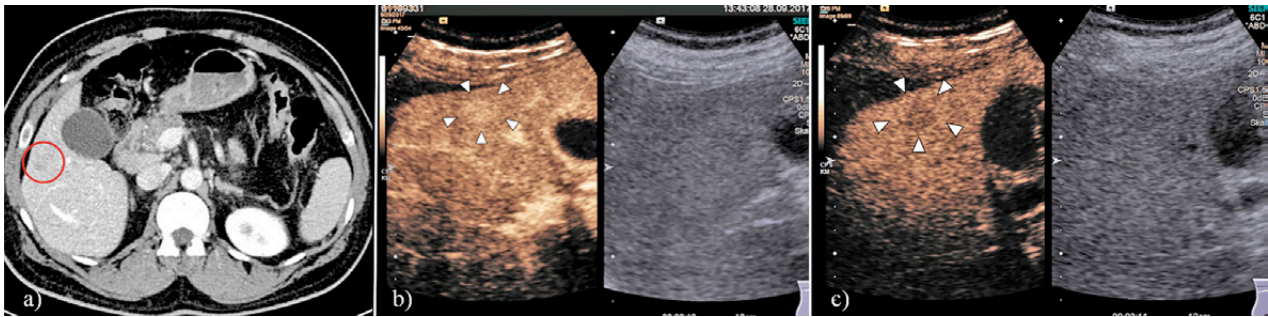
Med Ultrason

2023, Vol. 25, No 4, 435-444

Corresponding author: Prof. Dr. med. Christoph F. Dietrich  
Department Allgemeine Innere Medizin (DAIM)  
Kliniken Beau Site, Salem und Permanence,  
Hirslanden, Bern, CH-3036 Bern, Switzerland  
Tel: +41 764408150  
E-Mail: c.f.dietrich@googlemail.com

### Introduction

The World Federation for Ultrasound in Medicine and Biology (WFUMB) has published guidelines on the use of contrast-enhanced ultrasound (CEUS) for the evaluation of focal liver lesions [1-5]. Improved detection and characterization of common focal liver lesions (FLL) are the main topics of these guidelines.



**Fig 1.** Focal sarcoidosis of the liver (histological proven). 50 y/o male with chronic viral hepatitis C and bilateral hilar lymphadenopathy. Incidental finding of a hypoechoic focal liver lesion in liver segment 5 during computed tomography (a). Contrast enhanced ultrasound revealed a slightly hyperenhanced lesion during arterial phase (b) with washout during portal venous and late phase (c). Ultrasound-guided biopsy of the focal liver lesion and endoscopic ultrasound-guided transbronchial needle aspiration (EBUS-guided FNA) of the hilar lymph nodes both revealed sarcoidosis.

In this current paper series [6-11], we aim to summarize the US and CEUS features of very rare FLL where there are limited reports and figures published in order to create a library of these rare lesions. We cover lesions like autoimmune granuloma, inflammatory pseudotumor, regenerative nodules, solitary necrotic nodules of the liver, intrahepatic splenosis and intrahepatic endometriosis. The rarer the lesions are the more difficult it is to characterize them correctly, and the more frequently it is necessary to biopsy them. If we include those lesions into our diagnostic scheme the chances rise to misinterpret them as malignant. By this paper we like to motivate the reader to anticipate those lesions, and in doubt take the chance to biopsy those lesions.

#### **Autoimmune granuloma, granulomatous inflammatory infiltration**

Several granulomatous disorders can affect the liver. A granuloma is a focal accumulation of altered macrophages and other inflammatory cells that have developed in response to chronic exposure to infectious, non-infectious, or immune stimuli [12-14]. Hepatic involvement is often asymptomatic and found incidentally through imaging. Previous studies have reported a prevalence in up to 15% of biopsies [15,16]. The prevalence of such diseases differs depending on geographical region: in the United States, the most frequent cause is sarcoidosis, while in other countries such as India, tuberculosis represents the most common etiology (55% of all cases) [14]. Other etiologies include primary biliary cirrhosis, tuberculosis, tubercular-like infections, drugs, and malignancies. Despite its specific etiology, the granulomatous liver involvement manifests as diffuse and heterogeneous hypo- and sometimes also hyperechogenicity in US imaging or multiple echogenic nodules that are 3-5 mm in size and surrounded by a hypoechoic halo with scant vascularization [17].

#### **Hepatic sarcoidosis**

Sarcoidosis (SA) is a granulomatous disorder that can involve virtually every organ and tissue [18,19]. Less frequently, SA involves the liver and spleen with different clinical and imaging findings.

Ultrasound imaging can reveal various patterns. Non-specific and homogeneous hepatomegaly manifests as a homogeneous distribution of echoes, sometimes with increased echogenicity that mimics steatosis. An irregular pattern with a coarse appearance and inhomogeneity may be present, histologically represented by multiple granulomas of variable sizes and degrees of fibrosis [20]. Variably sized nodules (from 1-2 mm to 3-4 cm) can sometimes be found, and these most often manifest as multiple hypoechoic (or, less frequently, hyper- or isoechoic) lesions. Color Doppler US demonstrates hypovascularity [21]. In addition, splenic involvement can present with non-specific splenomegaly with or without focal lesions; these also appear as hypoechoic and hypovascular nodules of variable sizes [22]. Differential diagnosis with other lesions (mostly malignant ones) can be challenging, particularly if the patient has no other clinical or radiological clues of systemic sarcoidosis [23]. In such cases, CEUS can be useful in revealing variable arterial enhancement of the nodules and progressive hypo-enhancement in the portal venous and late phases. Although these characteristics can mimic malignant lesions [24], a typical pattern can be the presence of peripheral nodular contrast enhancement and a centripetal fill-in in the arterial phase [20,21] (fig 1).

#### **Inflammatory pseudotumor**

An inflammatory pseudotumor (IPT) is an uncommon benign tumor mostly observed in the lung. In a large cohort of extrapulmonary IPTs, only 8% were located in the liver [25,26]. Most IPTs of the liver appear as a

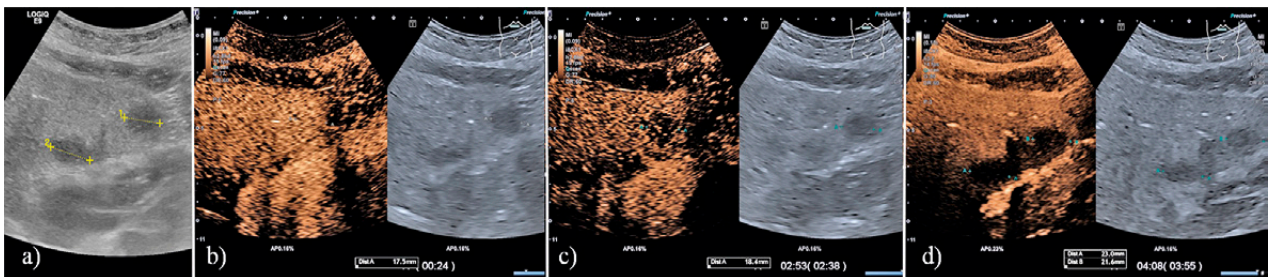
large solitary mass [27-29]. Histopathologically, IPTs are characterized by a lymphoplasmacellular inflammatory cell infiltration combined with fibroblast proliferation. Two histopathological types of IPT have been described: fibrohistiocytic and lymphoplasmacytic. The latter resembles focal autoimmune pancreatitis, is associated with sclerosing cholangitis, and possibly constitutes one particular manifestation of IgG4-related disease [30].

While older studies have considered the inflammatory myofibroblastic tumor (IMT) to be a subcategory of IPTs, it has recently been differentiated from the latter due to its uncertain biological behavior [31]. The aspect of IMT on ultrasound is unspecific, ranging from hypoechoic to hyperechoic, and either well- or ill-defined.

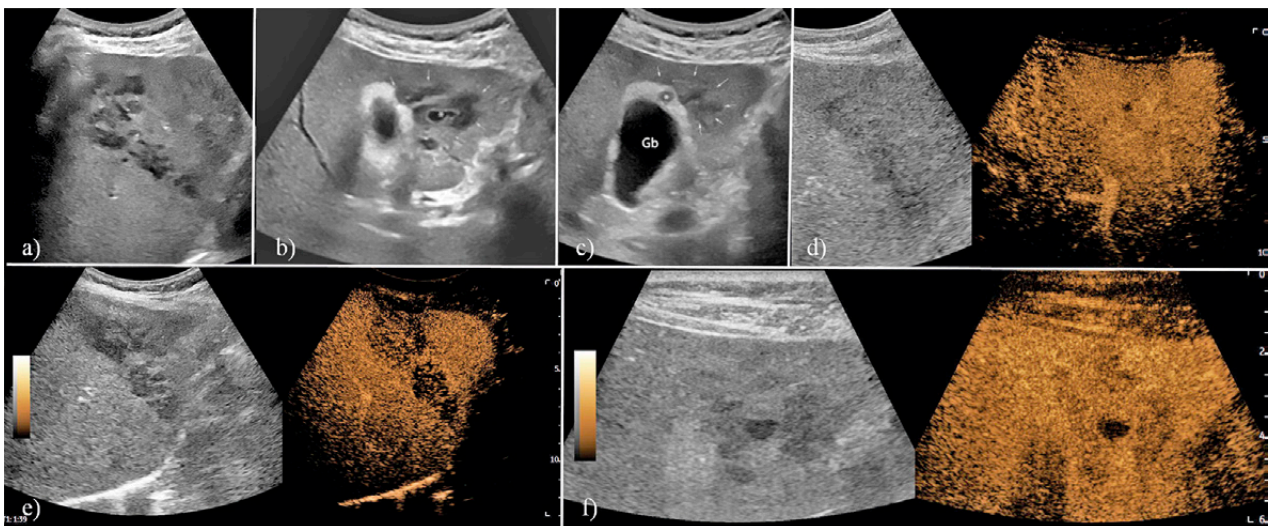
Often, they show arterial vascularity on Doppler. The pattern on CEUS is variable as well (either homogenous or heterogenous enhancement; peripheral or septal enhancement with delayed central filling and central lack of enhancement) [32].

Another very rare differential diagnosis is the neoplastic inflammatory pseudotumor-like follicular dendritic cell (IPT-like FDC) tumor [33,34].

A purely on imaging-based diagnosis of a hepatic IPT, IMT, or IPT-like FDC tumor is rarely possible, and in the majority of cases, a malignant liver tumor was suspected before surgery or biopsy [29,35]. Definitive diagnosis and differentiation from malignant liver tumors via imaging and image-guided percutaneous biopsy is essential for preventing unnecessary surgery.

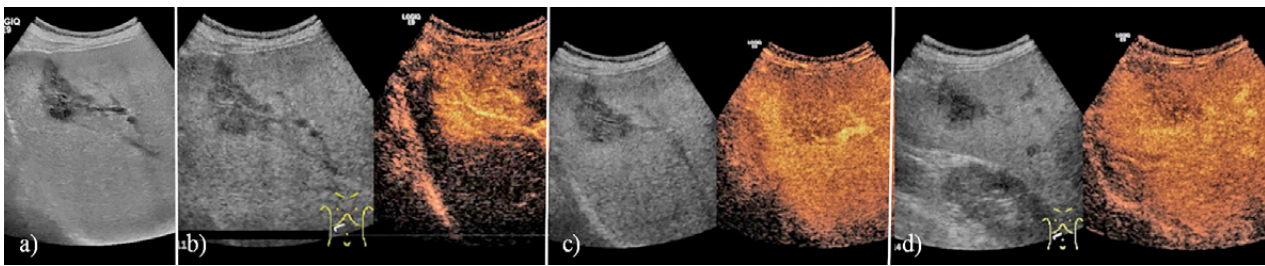


**Fig 2.** Inflammatory pseudotumor (histologically proven). In an 87-year-old woman with elevated liver enzymes, B-mode sonography delineated two hypoechoic liver lesions up to 2 cm with indistinct boundaries and a tumor like appearance (a). On CEUS, the arterial contrast enhancement was similar to the rest of the liver parenchyma for up to 30 seconds (b). In the portal and late phases, there was a slow washout phenomenon, which increased after 2 minutes (c) and was almost complete after 4 minutes (d). This finding suggested non-hepatic tissue. Ultrasound-guided biopsy confirmed IPT.

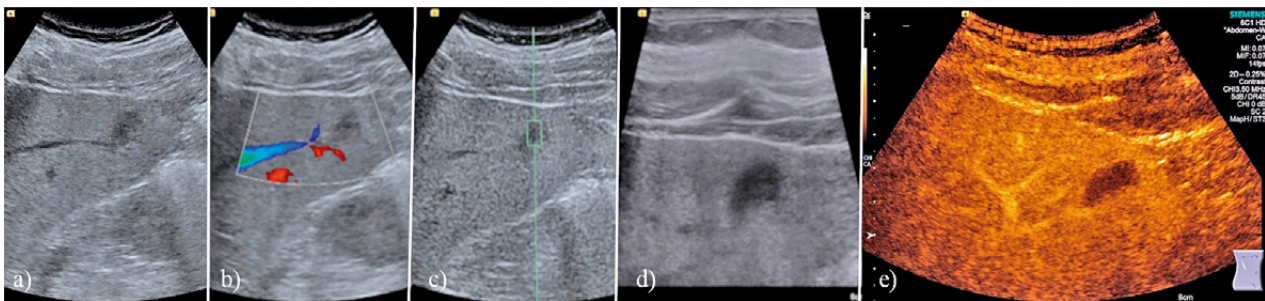


**Fig 3.** Incidental finding of a hepatic inflammatory pseudotumor. 79 y/o male, incidental ultrasound finding of a large, ill-defined, partially nodular hypoechoic lesion, which involved nearly all of segment 4 of the liver (a). It contained some anechoic (cystic) parts (b; cystic part) and focally involved the gallbladder wall (c; focal infiltration of gallbladder wall). Contrast-enhanced ultrasound showed arterial phase hyperenhancement of the whole segment 4 surrounding the hypoechoic lesion (d). There was slow and progressive washout in the portal-venous phase extending into the late phase (e, f). Ultrasound-guided biopsy revealed an EBV- and IgG4-related inflammatory pseudotumor.





**Fig 4.** Immunoglobulin G4 - associated pseudotumor (histologically proven). 46 y/o female presented with weight loss of 10 kg, elevated liver enzymes and alcohol abuse. There was also a history of chronic pancreatitis and pancreatic head resection for inflammatory phlegmon and also a background of steatosis hepatis. On B-mode sonography, an oval polycyclic bounded hypoechoic lesion is visible (a). Contrast-enhanced ultrasound showed arterial phase hyperenhancement (b). Starting with the portal-venous phase (c) and increasing into the late phase, the whole lesion showed progressive washout. Ultrasound-guided biopsy revealed IgG4-associated inflammatory pseudotumor. The treatment with prednisolone was started, which led to a reduction in the size of the pseudotumor. However, due to lack of compliance and continued alcohol use, this was terminated.



**Fig 5.** A case of inflammatory pseudotumor. A hypoechoic lesion with irregular shape and ill-defined margin was detected in the right liver lobe (a). No color flow signal was detected within the lesion (b). ARFI measurement showed the lesion was slightly hard ( $V_s=1.93$  m/s) (c). While using high frequency linear transducer, the lesion could be clearer visualized (d). After injection of contrast agent (SonoVue), the lesion showed hypoenhancement during all contrast enhancement phases (e).

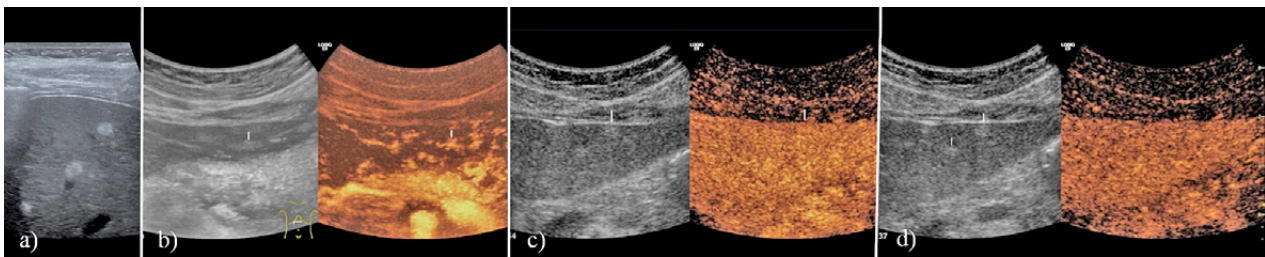
Most IPTs present with irregular margins. In US images, the majority of cases reveal an inhomogeneous hypoechoic or heterogeneous echo pattern [29,36].

One early case study reported a central dominated irregular vascularization followed by marked wash-out of the initial lesion [26]. One study reported a lack of enhancement in all three contrast phases in 19.4% of cases, diffuse homogeneous or heterogeneous arterial hyperenhancement in 61%, rim-like enhancement in 14%, and iso-enhancement in 6%. In the late and portal venous phases, hypo-enhancement was the predominant pattern [37]. In a later report, most of the lesions exhibited relatively mild arterial hyperenhancement (36%) or iso-enhancement (41%) with unclear margins (89%) in the arterial phase, either in a homogeneous (41%), heterogeneous (36%), or rim-like (23%) manner. Non-enhancing necrotic areas were common (57%). Washout occurred in 100% of the hepatic IPTs in the portal venous and late phases and in 66% of cases within 60 seconds. A “rapid in and out” pattern was observed in 41% of the IPT nodules. Based on the clinical and CEUS data, 45% are misdiagnosed as malignant tumors, particularly cholangiocarcinoma or metastasis [36] (fig 2-5).

### **Large regenerative nodules (LRNs), Nodular regenerative hyperplasia (NRH) and other well-differentiated hepatocellular nodules**

Large regenerative nodules are reactive hepatocellular nodules that develop in response to any kind of injury. First of all, they are observed in cirrhosis of the liver, but they may also occur in other non-cirrhotic entities such as chronic hepatitis B and C as well as in patients with systemic disorders such as Budd-Chiari syndrome (BCS), various autoimmune or hematological disorders, and congenital absence of the portal vein [38,39]. Multiple (more than 10) and smaller (less than 5 mm in diameter) lesions likely reflect NRH, whereas fewer (less than 10) and larger (greater than 10 mm in diameter) ones are categorized as LRNs [38,40].

The pathogenesis of NRH as well as that of large regenerative nodules (LRNs), including FNH-like ones, depends on an altered microcirculatory blood flow in the liver as a result of an obliterative vasculopathy [38,41]. Nodular regenerative hyperplasia has been described in patients with chronic use of certain medications, especially chemotherapeutic agents (such as oxaliplatin and



**Fig 6.** Morbus Wilson, nodular regenerative hyperplasia. 60 y/o female with weight loss, anaemia and initial diagnosis of plasmocytoma. B-mode ultrasound showed liver lesions up to 7 mm in size, with a hyperechoic rim and central hypoechogenicity (one might call it “atoll sign”) (a). On contrast-enhanced ultrasound, a spoke wheel-like hyperenhancement in the arterial phase was observed (see marking) (b). In the portal venous phase, iso-enhancement or slight hyperenhancement was still visible (c). In the late phase, the lesions were iso-enhanced (d).

azathioprine), and it has also been observed in a wide variety of systemic diseases that disturb hepatic blood flow, particularly myeloproliferative, lymphoproliferative, and immunological disorders [42]. In addition, various other conditions such as neoplastic disease, diabetes, celiac disease, cystic fibrosis and renal or bone marrow transplantation have been associated with NRH [43-46].

In US images, NRH nodules appear as either multiple confluent hyperechoic liver lesions or small, round isoechoic lesions with a thin hyperechoic rim (i.e., the atoll sign) [42]. Some nodules between 5 and 8 mm in size may harbor hyperenhancement in the arterial phase followed by a washout in the late phase resembling malignancy [41]. As these nodules could appear in oncological patients receiving chemotherapy, they should be differentiated from true liver metastases through a percutaneous liver biopsy (fig 6).

#### **FNH-like nodules**

Some hepatocellular nodules, particularly in vascular liver disease, show similarities between LRNs and FNHs; these are referred to as FNH-like nodules or FNH-like LRNs. Such nodules have only delicate fibrous septa instead of a central scar [38]. In CEUS, avid arterial enhancement starting from the center of the lesions and continuing centrifugally is present. In the portal venous and late phases, the lesions are iso-enhanced [47].

#### **Solitary necrotic nodule of the liver (SNNL)**

Typically, SNNLs are located in subcapsular regions, more frequently in the right liver lobe, and they appear as small lesions below 30 mm [48]. They are most frequently sharply demarcated [49]. Their form can sometimes indicate their etiology, since atypical shapes can appear in up to 50% of the cases.

Among benign focal liver lesions, the solitary necrotic nodule, is a very rare and poorly understood le-

sion of uncertain origin. The pathological hallmark of the SNNL is a core of coagulative and/or liquefied necrosis, surrounded by fibrohyaline tissue with palisaded histiocytes and a diffuse infiltrate of inflammatory cells such as lymphocytes, plasma cells, and eosinophils.

Several etiologic hypotheses have been proposed: (1) a necrotic lesion of traumatic origin [50,51]; (2) a sclerotic evolution of thrombosed small hemangiomas [52-54]; (3) the outcome of previous focal parasitic infestation [51,55]; and (4) a “burnout phase” of metastatic lesions [56].

Imaging diagnosis of SNNLs is difficult due to the overlap in findings with a wide range of malignant (e.g., primary liver cancers, lymphoma, and metastases) and benign (e.g., pseudotumor, regenerative, or dysplastic nodules in liver cirrhosis and infectious processes) conditions [57,58]. Since SNNLs are necrotic, imaging methods using contrast agents (CT, MRI, and US) typically reveal hypoenhancing lesions.

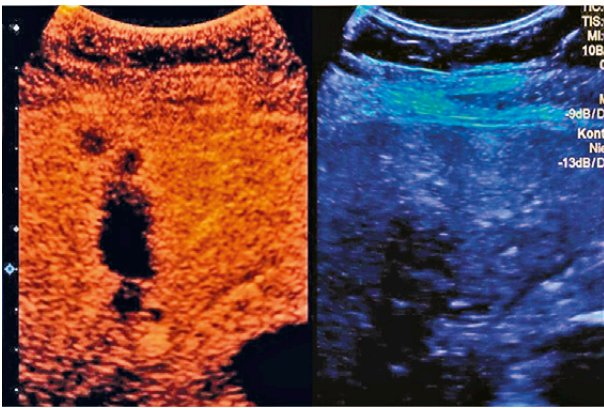
On B-mode US scans, SNNLs can appear mostly hypoechoic (75%), but they can also be iso- and hyperechoic. Such nodules more often present as small (on average less than 2 cm), single, right-sided (sometimes subcapsular), focal liver lesions with a homogeneously hypoechoic appearance; a “target” lesion is another frequent US presentation [59-61].

The diagnosis of SNNLs remains challenging even with CT, MRI, and PET, and they are frequently misdiagnosed as metastases [62,63].

Owing to the use of blood pool contrast agents [64] in CEUS in contradiction to CT and MRI, SNNLs appear completely free of any contrast uptake and are sharply demarcated. Between 2010 and 2020, Lu et al investigated 24 patients with up to 4 SNNLs using CEUS with SonoVue®. There was no enhancement in the center of any of the lesions, but rim enhancement was present in 13 out of the 24 cases. Rim enhancement with a rim of  $3 \pm 1.5$  mm tended to appear in larger lesions.

Reports on CEUS findings in SNNLs are scarce, and only one series with imaging-pathologic comparison has





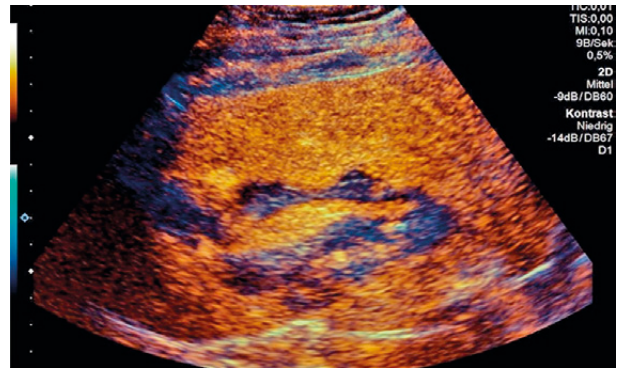
**Fig 7.** Contrast-enhanced imaging of solitary necrotic nodule with split imaging (note the sharp complete avascular serpiginous shaped lesion).

been published to date [65]. In CEUS examination with SonoVue®, SNNs appear unenhanced with sharp borders in the arterial phase and an unchanged appearance in the portal venous and late phases with no washout (i.e., a “punched-out-like” aspect) independent of size and B-mode US echo pattern [66]. The complete absence of a vascular network within the SNNL, a well-recognized pathological characteristic of this entity, explains the lack of peak arterial phase enhancement and consequently of washout. This aspect resembles the perfusion defects observed after the ablation of liver tumors [67]. In almost half of the cases, a notable additional CEUS finding of a thin, uniform, hyperenhancing rim occurring in the early arterial phase. The rim appears isoenhanced compared to the surrounding parenchyma in the late arterial, portal venous, and late phases and presents without any washout possibly as a consequence of the inflammatory reaction of the compressed adjacent parenchyma which causes vasodilation of the arterial microvessels (fig 7 and 8).

In conclusion, SNNs owing to the possibility of necrotic areas in metastases, US-guided biopsy should be considered in patients where the diagnosis remains uncertain.

### Intrahepatic splenosis

Splenosis corresponds to ectopic splenic tissue due to auto transplantation after splenic trauma and/or splenectomy. While accessory spleens are usually encapsulated, smooth-bordered, and round, splenosis has no capsule and no characteristic shape. Splenosis has no vascular hilum and receives its blood supply from surrounding tissues [68-71]. Intrahepatic splenosis is more frequently located in the left than in the right liver lobe perhaps due to anatomical reasons and is usually subcapsular [72,73]. Its significance lies in the diagnostic differentiation from



**Fig 8.** A complication from biopsy of a SNNL. After contrast injection, the overlay technique shows arterial enhancement in the intrahepatic hematoma which was treated conservatively.

other well vascularized liver tumours, especially in patients with pre-existing liver disease.

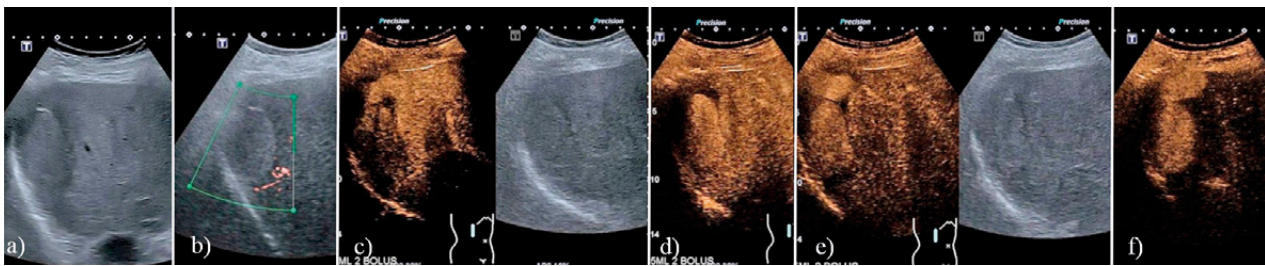
In B-mode US there are different characteristics of intrahepatic splenosis: oval or round, as a heterogeneous hypoechoic lesion with a hyperechoic rim [70], with a hypoechoic rim [74], as a well circumscribed [75] lesion or slightly more echogenic than the surrounding parenchyma [76] or a homogeneous rounded lesion, with demarcated margins [71]. Color Doppler shows a dotted and strip-like blood flow signal inside and around the lesions [71]. Splenosis and accessory spleens have similar characteristics on CEUS as the normal spleen [69,77]. CEUS is recommended for the diagnosis of ectopic splenic tissue by EFSUMB-Guidelines [77].

Zhong et al describe in their cases the typical expected CEUS behavior of intrahepatic splenomas with homogeneous hyperenhancement in the arterial phase without washout in the portal and late phase up to 4 min [70]. Nevertheless, differential diagnostic difficulties with some benign liver lesions may arise. (Shunt-)Haemangioma, FNH, some (inflammatory) hepatocellular adenomas are also hyperenhanced in the late phase on CEUS. Hyperenhancement after 2 min is considered a benign criterion of liver lesions [78].

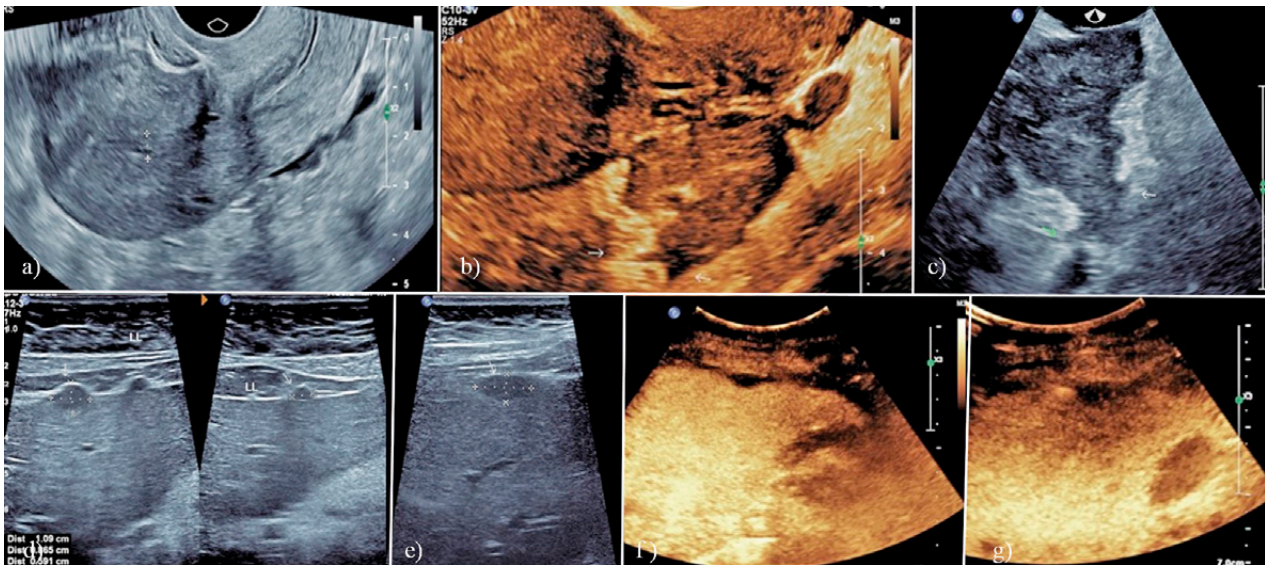
If a liver lesion is present in a liver-healthy patient with splenic trauma and/or splenectomy, the possibility of splenosis should be considered. The prolonged enhancement on CEUS may be indicative of such a condition. If there is pre-existing liver disease, the differential diagnosis is more difficult and HCC must be excluded. Usually HCCs are iso- or hypo-enhanced in the late phase and not persistently hyperenhancing on CEUS (fig 9).

### Intrahepatic endometriosis

In endometriosis, endometrial tissue is located outside the uterine cavity. Outside the pelvis, endometriosis



**Fig 9.** Intrahepatic splenosis. 50y/o, male. Motorbike accident 6 years ago with ruptured spleen and splenectomy. Current non-specific upper abdominal complaints. In B-mode ultrasonography oval focal lesion in the right liver lobe subcapsular. The lesion is slightly ill-defined and surrounded by hypoechoic rim (a). No vessels are visible in the lesion on Power Doppler (b). In the late arterial phase, the lesion is heterogeneous and less enhanced than the surrounding liver parenchyma (c). In the portal venous phase, the FLL is hyperenhanced (d). In the late phase, the FLL is hyperenhanced and a second hyperenhanced FLL is seen adjacent (e). Very late, 6:10 min post injection, both FLL are hyperenhanced, while the surrounding liver parenchyma shows no contrast (f). The very long-lasting contrast in the late phase in association with the history suggests the diagnosis of intrahepatic splenosis.



**Fig 10.** Hepatic endometriosis. Hypoechoic patches of endometriosis in pouch of Douglas (a). Endometriosis in the left adnexa (b). Endometriosis in the right adnexa (c). Hypoechoic lesions of endometriosis seen on the left liver lobe surface (d). Hypoechoic lesions of endometriosis seen on the right lobe surface (e). CEUS of the liver showing no intrinsic uptake of contrast agent by the lesion on the liver surface (f, g).

sis is rare. Reported intrahepatic cases described a wall structure either smooth, membranous, “ragged” or undulating and may have a wall-like structure at the periphery of the lesion [79].

The diagnosis of intrahepatic endometriosis is demanding. In the liver there are no clear differential diagnostic criteria compared to other tumors [80,81]. The diagnosis can only be made on basis of histopathological analysis.

Endometriotic lesions in the liver are mostly subcapsular. On B-mode ultrasonography most of the reported cases were cystic or heterogenous containing both cystic and solid components. Thick walled multiseptated cysts are commonly reported and punctate calcifications in the wall have been described [79,81-87] (fig 10).

### Conclusion

In this report, we focus on focal liver lesions of non-infectious and non-neoplastic origin.

Imaging features of rare lesions can resemble malignant or benign lesions and therefore pose a specific problem for diagnosis. Granulomatous disease (eg. tuberculosis and sarcoidosis) may involve the liver and these lesions can resemble malignant disease. Therefore, it is likely that its diagnosis has a relevant influence on the therapeutic strategy for the patient. Inflammatory pseudotumor, inflammatory myofibroblastic tumor and IPT-like FDC tumor resemble malignant lesions as well. Large regenerative nodules, NRH and FNH-like nodules have benign appearances and are important since they



may reflect relevant underlying diseases or relevant drug interactions. Solitary necrotic nodules should be known to every sonographer and although they have certain features on CEUS, they can mimic malignant lesions thus biopsy is inevitable. Intrahepatic splenosis should be considered in patients with history of splenectomy or splenic trauma and is characterized by a very long-lasting hyperenhancement. Intrahepatic endometriosis can be misinterpreted as sarcoma or neuroendocrine metastasis and will typically be biopsied.

The knowledge of rare FLL is crucial for any person performing liver imaging and / or intervention. In addition, hepatologists, oncologists and infectiologists need to understand the impact of rare FLL on their therapeutic strategy.

**Disclosures:** Some authors received speakers bureau and grants from Bracco and various ultrasound manufacturers.

## References

- Dietrich CF, Averkiou M, Nielsen MB, et al. How to perform Contrast-Enhanced Ultrasound (CEUS). *Ultrasound Int Open* 2018;4:E2-E15.
- Claudon M, Dietrich CF, Choi BI, et al. Guidelines and good clinical practice recommendations for contrast enhanced ultrasound (CEUS) in the liver—update 2012: a WFUMB-EFSUMB initiative in cooperation with representatives of AFSUMB, AIUM, ASUM, FLAUS and ICUS. *Ultraschall Med* 2013;34:11-29.
- Claudon M, Dietrich CF, Choi BI, et al. Guidelines and good clinical practice recommendations for Contrast Enhanced Ultrasound (CEUS) in the liver - update 2012: A WFUMB-EFSUMB initiative in cooperation with representatives of AFSUMB, AIUM, ASUM, FLAUS and ICUS. *Ultrasound Med Biol* 2013;39:187-210.
- Dietrich CF, Nolsoe CP, Barr RG, et al. Guidelines and Good Clinical Practice Recommendations for Contrast-Enhanced Ultrasound (CEUS) in the Liver-Update 2020 WFUMB in Cooperation with EFSUMB, AFSUMB, AIUM, and FLAUS. *Ultrasound Med Biol* 2020;46:2579-2604.
- Dietrich CF, Nolsoe CP, Barr RG, et al. Guidelines and Good Clinical Practice Recommendations for Contrast Enhanced Ultrasound (CEUS) in the Liver - Update 2020 - WFUMB in Cooperation with EFSUMB, AFSUMB, AIUM, and FLAUS. *Ultraschall Med* 2020;41:562-585.
- Zander T, Zadeh ES, Möller K, et al. Comments and illustrations of the WFUMB CEUS liver guidelines: Rare focal liver lesion - infectious parasitic, fungus. *Med Ultrason* 2023, doi: 10.11152/mu-4091.
- Ignee A, Möller K, Thees-Laurenz R, et al. Comments and illustrations of the WFUMB CEUS liver guidelines: Rare focal liver lesions - infectious (bacterial). *Med Ultrason* 2023, doi 10.11152/mu-4065.
- Möller K, Braden B, Culver EL, et al. Secondary sclerosing cholangitis and IgG4-sclerosing cholangitis - A review of cholangiographic and ultrasound imaging. *Endosc Ultrasound* 2023;12:181-199.
- Möller K, Safai Zadeh E, Görg C, et al. Prevalence of benign focal liver lesions and non-hepatocellular carcinoma malignant lesions in liver cirrhosis. *Z Gastroenterol* 2023;61:526-535.
- Möller K, Safai Zadeh E, Görg C, et al. Focal Liver Lesions other than Hepatocellular Carcinoma in Cirrhosis: Diagnostic Challenges. *J Transl Int Med* 2022;10:308-327.
- Möller K, Tscheu T, De Molo C, et al. Comments and illustrations of the WFUMB CEUS liver guidelines: rare congenital vascular pathology. *Med Ultrason* 2022;24:461-472.
- Tchernev G, Tana C, Schiavone C, Cardoso JC, Ananiev J, Wollina U. Sarcoidosis vs. Sarcoid-like reactions: The Two Sides of the same Coin? *Wien Med Wochenschr* 2014;164:247-259.
- Tchernev G, Chokoeva AA, Tana M, Tana C. Transcriptional blood signatures of sarcoidosis, sarcoid-like reactions and tuberculosis and their diagnostic implications. *Sarcoidosis Vasc Diffuse Lung Dis* 2016;33:5030.
- Coash M, Forouhar F, Wu CH, Wu GY. Granulomatous liver diseases: a review. *J Formos Med Assoc* 2012;111:3-13.
- Neville E, Piyasena KH, James DG. Granulomas of the liver. *Postgrad Med J* 1975;51:361-365.
- Satti MB, al-Freihi H, Ibrahim EM, et al. Hepatic granuloma in Saudi Arabia: a clinicopathological study of 59 cases. *Am J Gastroenterol* 1990;85:669-674.
- Mills P, Saverymuttu S, Fallowfield M, Nussey S, Joseph AE. Ultrasound in the diagnosis of granulomatous liver disease. *Clin Radiol* 1990;41:113-115.
- Tana C, Giamberardino MA, Di Gioacchino M, Mezzetti A, Schiavone C. Immunopathogenesis of sarcoidosis and risk of malignancy: a lost truth? *Int J Immunopathol Pharmacol* 2013;26:305-313.
- Chokoeva AA, Tchernev G, Tana M, Tana C. Exclusion criteria for sarcoidosis: A novel approach for an ancient disease? *Eur J Intern Med* 2014;25:e120.
- Palmucci S, Torrisi SE, Caltabiano DC, Puglisi S, Lentini V, Grassettonio E, Vindigni V, et al. Clinical and radiological features of extra-pulmonary sarcoidosis: a pictorial essay. *Insights Imaging* 2016;7:571-587.
- Tana C, Schiavone C, Ticinesi A, et al. Ultrasound imaging of abdominal sarcoidosis: State of the art. *World J Clin Cases* 2019;7:809-818.
- Tana C, Iannetti G, Mezzetti A, Schiavone C. Splenic sarcoidosis remains a diagnostic challenge. *J Clin Ultrasound* 2014;42:156.
- Chokoeva AA, Tchernev G, Tana C, Ananiev J, Wollina U. Sarcoid-like pattern in a patient with tuberculosis. *J Biol Regul Homeost Agents* 2014;28:783-788.
- Tana C, Iannetti G, D'Alessandro P, Tana M, Mezzetti A, Schiavone C. Pitfalls of contrast-enhanced ultrasound (CEUS) in the diagnosis of splenic sarcoidosis. *J Ultrasound* 2013;16:75-80.



25. Coffin CM, Humphrey PA, Dehner LP. Extrapulmonary inflammatory myofibroblastic tumor: a clinical and pathological survey. *Semin Diagn Pathol* 1998;15:85-101.
26. Schuessler G, Fellbaum C, Fauth F, et al. [The inflammatory pseudotumour -- an unusual liver tumour]. *Ultraschall Med* 2006;27:273-279.
27. Goldsmith PJ, Loganathan A, Jacob M, et al. Inflammatory pseudotumours of the liver: a spectrum of presentation and management options. *Eur J Surg Oncol* 2009;35:1295-1298.
28. Park JY, Choi MS, Lim YS, et al. Clinical features, image findings, and prognosis of inflammatory pseudotumor of the liver: a multicenter experience of 45 cases. *Gut Liver* 2014;8:58-63.
29. Yang X, Zhu J, Biskup E, Cai F, Li A. Inflammatory pseudotumors of the liver: experience of 114 cases. *Tumour Biol* 2015;36:5143-5148.
30. Zen Y, Fujii T, Sato Y, Masuda S, Nakanuma Y. Pathological classification of hepatic inflammatory pseudotumor with respect to IgG4-related disease. *Mod Pathol* 2007;20:884-894.
31. Elpek GO. Inflammatory Myofibroblastic Tumor of the Liver: A Diagnostic Challenge. *J Clin Transl Hepatol* 2014;2:53-57.
32. Nam KJ, Kang HK, Lim JH. Inflammatory pseudotumor of the liver: CT and sonographic findings. *AJR Am J Roentgenol* 1996;167:485-487.
33. Ge R, Liu C, Yin X, Chen J, et al. Clinicopathologic characteristics of inflammatory pseudotumor-like follicular dendritic cell sarcoma. *Int J Clin Exp Pathol* 2014;7:2421-2429.
34. Martins PN, Reddy S, Martins AB, Facciuto M. Follicular dendritic cell sarcoma of the liver: unusual presentation of a rare tumor and literature review. *Hepatobiliary Pancreat Dis Int* 2011;10:443-445.
35. Tang L, Lai EC, Cong WM, et al. Inflammatory myofibroblastic tumor of the liver: a cohort study. *World J Surg* 2010;34:309-313.
36. Kong WT, Wang WP, Shen HY, et al. Hepatic inflammatory pseudotumor mimicking malignancy: the value of differential diagnosis on contrast enhanced ultrasound. *Med Ultrason* 2021;23:15-21.
37. Kong WT, Wang WP, Cai H, Huang BJ, Ding H, Mao F. The analysis of enhancement pattern of hepatic inflammatory pseudotumor on contrast-enhanced ultrasound. *Abdom Imaging* 2014;39:168-174.
38. Sempoux C, Balabaud C, Paradis V, Bioulac-Sage P. Hepatocellular nodules in vascular liver diseases. *Virchows Arch* 2018;473:33-44.
39. Ueda T, Starkey J, Mori K, et al. A pictorial review of benign hepatocellular nodular lesions: comprehensive radiological assessment incorporating the concept of anomalous portal tract syndrome. *J Hepatobiliary Pancreat Sci* 2011;18:386-396.
40. Vilgrain V, Paradis V, Van Wettere M, Valla D, Ronot M, Rautou PE. Benign and malignant hepatocellular lesions in patients with vascular liver diseases. *Abdom Radiol (NY)* 2018;43:1968-1977.
41. Hopfner M, Scheel AH, Braun M, Ruschoff J, Loser C. Unusual Nodular Regenerative Hyperplasia Mimicking Liver Metastases in CEUS. *Ultraschall Med* 2014;35:199-202.
42. Caturelli E, Ghittoni G, Ranalli TV, Gomes VV. Nodular regenerative hyperplasia of the liver: coral atoll-like lesions on ultrasound are characteristic in predisposed patients. *Br J Radiol* 2011;84:e129-134.
43. Issa Z, Gohy S, Zech F, Baldin P, Delire B, Dahlqvist G. Prevalence and characteristics of cystic fibrosis liver disease: a study highlighting the lack of histological diagnosis. *Clin Res Hepatol Gastroenterol* 2022;46:101977.
44. Bargon J, Stein J, Dietrich CF, Müller U, Caspary WF, Wagner TO. [Gastrointestinal complications of adult patients with cystic fibrosis]. *Z Gastroenterol* 1999;37:739-749.
45. Dietrich CF, Chichakli M, Hirche TO, et al. Sonographic findings of the hepatobiliary-pancreatic system in adult patients with cystic fibrosis. *J Ultrasound Med* 2002;21:409-416; quiz 417.
46. Dietrich CF, Hollerweger A, Dirks K, et al. EFSUMB Gastrointestinal Ultrasound (GIUS) Task Force Group: Celiac sprue and other rare gastrointestinal diseases ultrasound features. *Med Ultrason* 2019;21:299-315.
47. Newerla C, Schaeffer F, Terracciano L, Hohmann J. Multiple FNH-Like Lesions in a Patient with Chronic Budd-Chiari Syndrome: Gd-EOB-Enhanced MRI and BR1 CEUS Findings. *Case Rep Radiol* 2012;2012:685486.
48. Fang J, Ma X, Yu D, Ma X, Xiang Y, Guo L. Specific imaging characteristic of solitary necrotic nodule of the liver: Marked peripheral rim-like enhancement with internal hypointensity on longer delayed MRI. *Eur Radiol* 2017;27:3563-3573.
49. Pananwala H, Pang TC, Eckstein RP, et al. The enigma of solitary necrotic nodule of the liver. *ANZ J Surg* 2014;84:260-265.
50. Shepherd NA, Lee G. Solitary necrotic nodules of the liver simulating hepatic metastases. *J Clin Pathol* 1983;36:1181-1183.
51. Tsui WM, Yuen RW, Chow LT, Tse CC. Solitary necrotic nodule of the liver: parasitic origin? *J Clin Pathol* 1992;45:975-978.
52. Berry CL. Solitary "necrotic nodule" of the liver: a probable pathogenesis. *J Clin Pathol* 1985;38:1278-1280.
53. Sundaresan M, Lyons B, Akosa AB. 'Solitary' necrotic nodules of the liver: an aetiology reaffirmed. *Gut* 1991;32:1378-1380.
54. Koea J, Taylor G, Miller M, Rodgers M, McCall J. Solitary necrotic nodule of the liver: a riddle that is difficult to answer. *J Gastrointest Surg* 2003;7:627-630.
55. Clouston AD, Walker NI, Procvic P. Parasitic origin of a solitary necrotic nodule of the liver. *J Clin Pathol* 1993;46:578.
56. Deniz K, Coban G. Solitary necrotic nodule of the liver: always benign? *J Gastrointest Surg* 2010;14:536-540.
57. Geng L, Lin C, Huang B, et al. Solitary necrotic nodule of the liver: MR findings in 33 pathologically proved lesions. *Eur J Radiol* 2012;81:623-629.

58. Wang LX, Liu K, Lin GW, Zhai RY. Solitary Necrotic Nodules of the Liver: Histology and Diagnosis With CT and MRI. *Hepat Mon* 2012;12:e6212.
59. Imura S, Miyake K, Ikemoto T, et al. Rapid-growing solitary necrotic nodule of the liver. *J Med Invest* 2006;53:325-329.
60. De Luca M, Luigi B, Formisano C, et al. Solitary necrotic nodule of the liver misinterpreted as malignant lesion: considerations on two cases. *J Surg Oncol* 2000;74:219-222.
61. Choi CS, Cho EY, Jeong JS, Im CJ, Yang BJ, Kim HC. Spontaneous regression of a solitary necrotic nodule of the liver. *Hepatol Int* 2010;4:649-652.
62. Hwang JY, Lee JE, Jung MJ. A Challenging Case of Solitary Necrotic Nodules of the Liver Mimicking Hepatic Metastases: CT, MRI, and PET-CT Findings. *J Belg Soc Radiol* 2020;104:16.
63. Qian H, Li S, Ji M, Lin G. MRI characteristics for the differential diagnosis of benign and malignant small solitary hypovascular hepatic nodules. *Eur J Gastroenterol Hepatol* 2016;28:749-756.
64. Ignee A, Atkinson NS, Schuessler G, Dietrich CF. Ultrasound contrast agents. *Endosc Ultrasound* 2016;5:355-362.
65. Wang Y, Yu X, Tang J, Li H, Liu L, Gao Y. Solitary necrotic nodule of the liver: contrast-enhanced sonography. *J Clin Ultrasound* 2007;35:177-181.
66. Francica G, Meloni MF, Riccardi L, de Sio I, et al. Contrast-Enhanced Ultrasound Findings in Patients with Rare Solitary Necrotic Nodule of the Liver - a Multicenter Report. *Ultraschall Med.* 2023; 44: 81-88.
67. Meloni MF, Francica G, Chiang J, Coltorti A, Danzi R, Laeseke PF. Use of Contrast-Enhanced Ultrasound in Ablation Therapy of HCC: Planning, Guiding, and Assessing Treatment Response. *J Ultrasound Med* 2021;40:879-894.
68. Gandhi D, Sharma P, Garg G, Songmen S, Solanki S, Singh T. Intrahepatic splenosis demonstrated by diffusion weighted MRI with histologic confirmation. *Radiol Case Rep* 2020;15:602-606.
69. De Robertis R, D'Onofrio M, Manfrin E, Dal Bo C, Pozzi Mucelli R. A rare case of pancreatic head splenosis diagnosed by contrast-enhanced ultrasound. *Ultraschall Med* 2014;35:72-74.
70. Sato N, Abe T, Suzuki N, et al. Intrahepatic splenosis in a chronic hepatitis C patient with no history of splenic trauma mimicking hepatocellular carcinoma. *Am J Case Rep* 2014;15:416-420.
71. Zhong X, Yang L, Huang J, Deng L, Nie L, Lu Q. Contrast-enhanced ultrasonographic imaging of hepatic splenosis: A case report. *Medicine (Baltimore)* 2021;100:e24243.
72. Luo X, Zeng J, Wang Y, Min Y, et al. Hepatic splenosis: Rare yet important - A case report and literature review. *J Int Med Res* 2019;47:1793-1801.
73. Ananthan K, Yusuf GT, Kumar M. Intrahepatic and intra-abdominal splenosis: A case report and review of literature. *World J Hepatol* 2019;11:773-779.
74. Dolle M, Ringe KI, Hartleben B, et al. [A supposed hepatocellular adenoma turns out to be intrahepatic splenosis - a case report]. *Z Gastroenterol* 2021;59:149-152.
75. Liu C, Liu J, Wang F. Intrahepatic splenosis mimicking liver cancer: report of a case and review of literature. *Int J Clin Exp Pathol* 2015;8:1031-1035.
76. Sansone V, Falsetti L, Tovoli F, Golfieri R, Cescon M, Piscaglia F. An Uncommon Focal Liver Lesion: Intrahepatic Splenosis. *J Gastrointestin Liver Dis* 2020;29:257-262.
77. Sidhu PS, Cantisani V, Dietrich CF, et al. The EFSUMB Guidelines and Recommendations for the Clinical Practice of Contrast-Enhanced Ultrasound (CEUS) in Non-Hepatic Applications: Update 2017 (Long Version). *Ultraschall Med* 2018;39:e2-e44.
78. Dietrich CF. Contrast-Enhanced Ultrasound of Benign Focal Liver Lesions. *Ultraschall Med* 2019;40:12-29.
79. Inal M, Bicakci K, Soyupak S, et al. Hepatic endometrioma: a case report and review of the literature. *Eur Radiol* 2000;10:431-434.
80. Liu K, Zhang W, Liu S, Dong B, Liu Y. Hepatic endometriosis: a rare case and review of the literature. *Eur J Med Res* 2015;20:48.
81. Sherif AM, Musa ER, Kedar R, Fu L. Subcapsular hepatic endometriosis: case report and review of the literature. *Radiol Case Rep* 2016;11:303-308.
82. Finkel L, Marchevsky A, Cohen B. Endometrial cyst of the liver. *Am J Gastroenterol* 1986;81:576-578.
83. Goldsmith PJ, Ahmad N, Dasgupta D, Campbell J, Guthrie JA, Lodge JP. Case hepatic endometriosis: a continuing diagnostic dilemma. *HPB Surg* 2009;2009:407206.
84. Keramidaris D, Gourgiotis S, Koutela A, et al. Rare Case of Hepatic Endometriosis as an Incidental Finding: Difficult Diagnosis of a Diagnostic Dilemma. *Ann Hepatol* 2018;17:884-887.
85. Khan AW, Craig M, Jarmulowicz M, Davidson BR. Liver tumours due to endometriosis and endometrial stromal sarcoma. *HPB (Oxford)* 2002;4:43-45.
86. Rivkine E, Jakubowicz D, Marciano L, et al. Hepatic endometrioma: a case report and review of the literature: report of a case. *Surg Today* 2013;43:1188-1193.
87. Rana P, Haghighat S, Han H. Endometrioma of the Liver: A Case Report and Review of the Literature. *Case Reports Hepatol* 2019;2019:4734606.