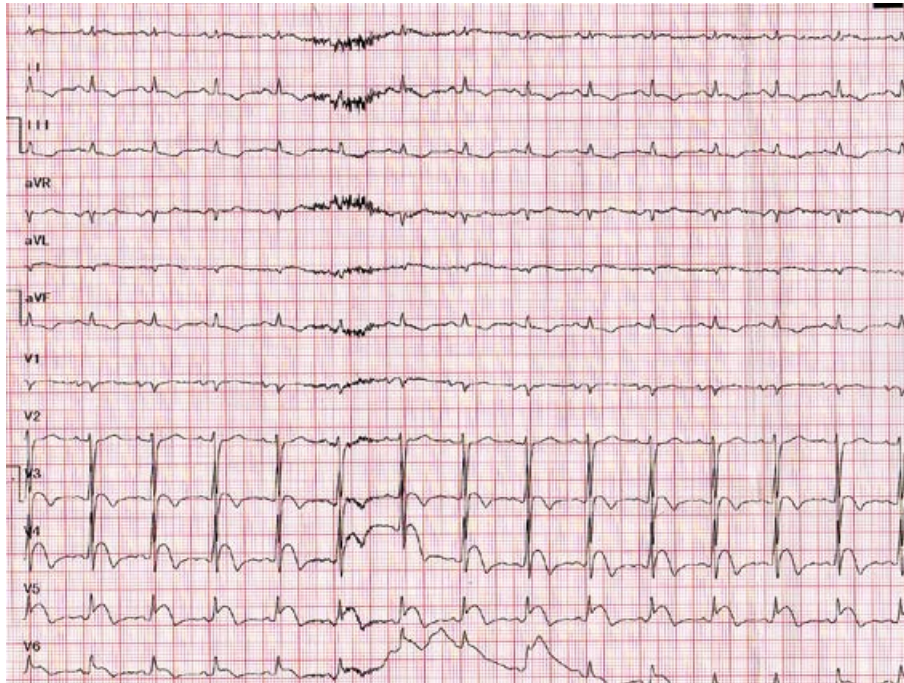
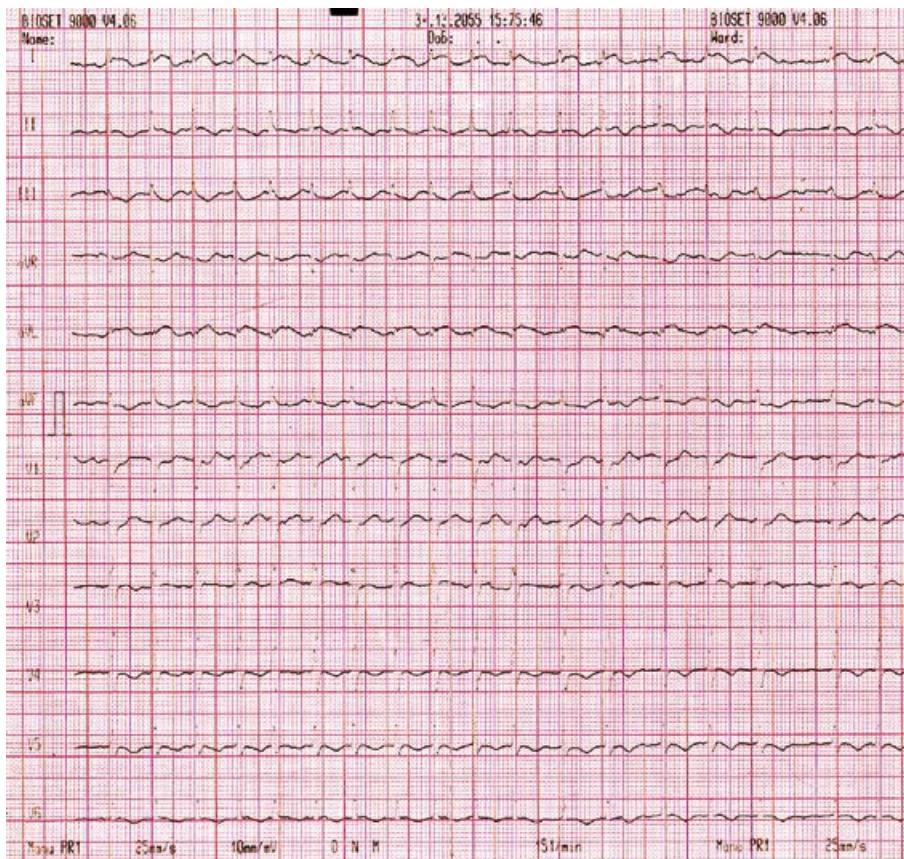


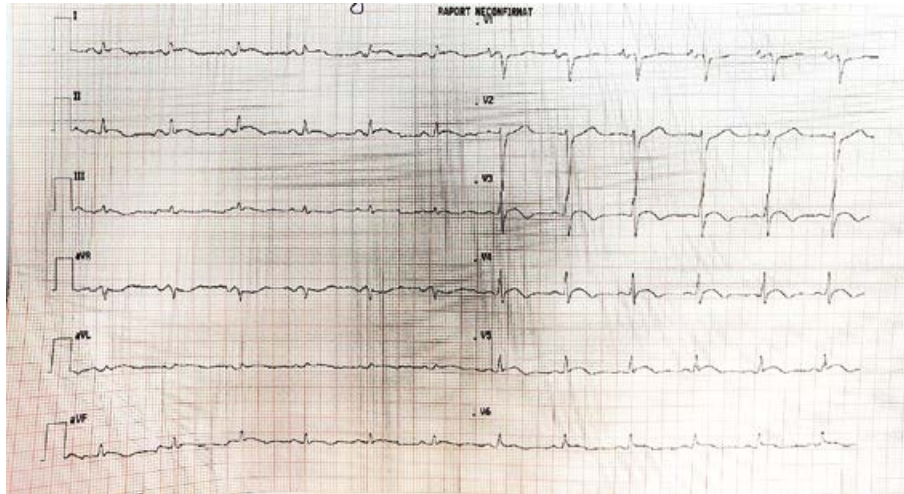
Supplementary figures



Supplemental figure 1. ECG in the emergency department: ST segment elevation of 1-4 mm in leads DI, aVL, V3-V6.



Supplemental figure 2. The ECG during hospitalization in the intensive coronary unit. Atrial fibrillation with rapid ventricular transmission



**Supplemental figure 3.** The ECG at 2 weeks follow up. Persistent ST-segment elevation of 1-3 mm in leads DI, DII, aVL, V3-V6