

ARFI quantitative elastography of the submandibular glands. Normal measurements and the diagnosis value of the method in radiation submaxillitis.

Alexandru Florin Badea¹, Attila Tamas Szora², Elisabeta Ciuleanu³, Ioana Chioreanu⁴, Grigore Băciu¹, Monica Lușor Platon², Radu Badea²

¹Department of Maxillofacial Surgery, "Iuliu Hațieganu" University of Medicine and pharmacy, ²Imaging Department, "O. Fodor" Institute of Gastroenterology and Hepatology, "Iuliu Hațieganu" University of Medicine and Pharmacy, ³Radiotherapy Department, "Ioan Chiricuța" Oncologic Institute, ⁴Department of Mathematics, Babeș-Bolyai University, Cluj Napoca, Romania

Abstract

Objectives: Evaluation of Acoustic Radiation Force Impulse Imaging (ARFI) elastography performance in predicting the elasticity of the submandibular glands in normal situations and after radiation therapy. **Material and method:** A number of 54 normal submandibular glands from 27 voluntary subjects and 33 pathological submandibular glands (radiation submaxillitis) from 18 patients who had undergone radiation therapy for various cervical and facial oncological conditions were included in study. All the patients had undergone a B mode ultrasonography (Tissue Harmonic Imaging, 8-14 MHz) while the submandibular volume was determined and subsequently an ARFI examination while the shear wave velocity (SWV) was measured (in the central, peripheral and subcapsular areas, with the results expressed in m/s). **Results:** In the volunteers' group the mean value of the SWV of the left submandibular gland was 1.68 ± 0.46 m/s, determined in the centre of the gland, 1.88 ± 0.4 m/s in the periphery (corresponding to the subcapsular parenchyma) and the SWV of the right submandibular gland was 1.74 ± 0.35 m/s (centrally) and 1.84 ± 0.43 m/s in the periphery. The mean value of all measurements was 1.82 ± 0.41 m/s. The mean volume of the glands was 7.97 ± 2.63 cm³. In the group of patients who had underwent radiation therapy (at least 35Gy), the mean value of the SWV was 2.24 ± 0.49 m/s centrally and 2.1 ± 0.58 m/s in the periphery on the left and 1.99 ± 0.5 m/s centrally and 2.21 ± 0.52 m/s in the periphery on the right. The mean value of all the measurements was 2.13 ± 0.52 m/s and the mean volume of the gland was 5.95 ± 4.16 cm³. **Conclusions:** Elastography using ARFI technique is a valid examination in the evaluation of the normal and pathological submandibular gland stiffness. The values of the shear wave velocities that correspond to a normal stiffness, determined through the ARFI technique, are similar in the two glands. After cervical and facial radiation therapy the values of the SWV are increased, indicating a change in the consistency of the gland thus implying a structural transformation. The ARFI technique can be used in the evaluation of the salivary glands pathology.

Keywords: ultrasonography, elastography, ARFI, submandibular gland, radiation therapy.

Introduction

The pathology of the salivary glands comprises numerous inflammatory and tumoral, degenerative and in-

fectious conditions. A physical examination is essential in order to establish an initial diagnosis in relationship with the history of the disease. Yet the accuracy of the physical exam is limited since there are several conditions that share similar symptoms. This is the reason why physicians usually request further investigations, one of them being ultrasonography (US) [1].

US has been proved to have applications in the evaluation of the anatomy and vascularity of the salivary glands, including the submandibular glands [2]. The method easily identifies tumoral masses, assesses their consistency, elasticity, as well as the features of the vascularity. These criteria, when used together, are extreme-

Received 15.05.2013 Accepted 22.06.2013

Med Ultrason

2013, Vol. 15, No 3, 173-179

Corresponding author: Attila Tamas Szora,

Imaging Department, "O. Fodor"

Gastroenterology and Hepatology Institute

"Iuliu Hațieganu" University of Medicine

and Pharmacy

19-21 Croitorilor str, 400162, Cluj Napoca, România

Email: tamas-szora.attila@umfcluj.ro

ly useful in defining the nature of a tumoral mass as close to reality as possible. Additionally, the use of US in tumor staging by assessing local invasion and by identifying tumoral lymph nodes is well-known. US can also be used in diffuse pathology of the submandibular glands.

An increased volume of the gland associated with a structural alteration can lead the diagnosis. The Doppler interrogation, and lately the contrast-enhanced exam, consolidates the diagnosis of inflammation. The diagnosis is based on the increase of the signal identified in the vessels, on the number of vessels and their spatial distribution as well as the microbubbles features of transition through the gland [3].

In the latter years there have been many discussions regarding elastographic procedures. These techniques are meant to objectively appreciate the real consistency of a structure located in a certain topographic region [4]. There are several types of elastographic examinations [5]. The “real-time” elastography (quasistatic elastography - SE) is a method which color codes the deformability of a region of interest upon which the transducers is repeatedly, uniformly pressed with low amplitude. The method has proved useful in breast pathology as well as in thyroid pathology [6,7]. The disadvantage of the method is operator-dependency, the image being conditioned both by the modality by which the region of interest is being pressed as well as by the experience of the examiner. Additionally, the obtained data are semiquantitative. Unidimensional transient elastography expresses in kilopascals the tissue stiffness evaluated by using an ultrasound beam issued on a predefined direction. The method has proved its value in quantifying the degree of liver fibrosis, replacing in certain circumstances liver biopsy [8]. Another elastographic procedure is represented by shear wave elastography (SWE), where the transducer is held steady on the examined region and the image is produced by successive pulses of different acoustic power (“pushing” waves) and by an ultrafast technique of detecting the implicit variation of the tissues [9]. The information obtained is color-coded, thus having the advantage of a superior theoretical accuracy and operator independence and also an independence from the physiological shape variation of the surrounding textures. This technique allows the discrimination between benign and malignant thyroid nodules [10]. Color-coded static elastographic procedures have a global disadvantage of being semiquantitative. They first emphasize the tumoral masses when these have different stiffness from that of the surrounding parenchyma [11]. The information provided through color-coded procedures regarding the submandibular parenchyma in diffuse conditions is discouraged as it is considered just guiding and highly subjective [12].

A technique that has been just recently introduced in practice is the ARFI technique (Acoustic Radiation Force Impulse). ARFI imaging technology involves the mechanical excitation of tissue using short-duration acoustic pulses (< 1 ms) in a region of interest chosen by the examiner, producing shear waves that spread away from the region of interest, perpendicularly to the acoustic push pulse, generating a localized, micron-scale displacement of the tissue. Simultaneously, detection waves of lower intensity than that of the push pulse (1:100) are generated. The moment of interaction between the shear waves and detection waves marks the period of time elapsed between the generating of shear waves and their entire crossing of the region of interest. By recording the shear wavefront at several locations and correlating these measurements with the elapsed time, the shear wave velocity (SWV) (m/s) can be quantified; generally, the stiffer a region in the tissue, the greater the SWV as it travels through this region. Thus, the measured SWV is an intrinsic characteristic of the tissue. There are already studies that show that the method can be used in clinical practice in evaluating fibrosis in various liver conditions [13].

The **aims** of the present study are: to find the mean values of the SWV of the normal submandibular glands (SMG) and to identify the alterations of the mean SWV of the SMG in patients who undergo cervical and facial radiotherapy procedures for different oncological conditions.

Material and method

This is a prospective study, focused on the submandibular glands, performed between February and April 2012. The Ethics Committee of the “Iuliu Hațieganu” University of Medicine and Pharmacy, Cluj-Napoca approved the study. The procedure was explained to all patients and a written informed consent obtained from them. All the patients were examined using a standardized procedure consisting of a B mode, grey-scale and color Doppler (CFM) exploration and an elastographic examination through the ARFI technique.

Study group. The study group comprised 45 volunteers, divided into two subgroups: subgroup A, which included healthy subjects, was used to define the normal values of the SWV in the SMG; subgroup B, which included the patients that underwent radiation therapy, was used for validating the ARFI technique for pathological situations.

Subgroup A consisted of 27 subjects (male:female = 10:17), with a mean age of 27 ± 8.7 years old (range 19 - 51 years), and it was considered the reference group. The including criteria were: normal general status, no previ-

ous pathology that might have had consequences on the salivary glands, normal results of the usual biochemical tests, normal salivation demonstrated through a standardized salivation test, normal US aspect on grey scale and Doppler examination. The excluding criteria were represented by an altered salivation felt by the subject, a history of previous diseases of the salivary glands, ultrasonographic changes of the submandibular glands parenchyma, radiation therapy on the cervical region.

Subgroup B consisted of 18 subjects (male:female = 13:5), with a mean age of 51 ± 10.9 years old (range 28 - 67 years). The including criteria in this subgroup were represented by: history of radiation therapy procedures of at least 35 Gy on the cervical region, at least 6 months since the last exposure, changes of the salivation demonstrated through the salivation test, normal general status, normal biochemical tests. Excluding criteria were represented by: age over 70 years old. Three of the patients from this group presented a single submandibular gland since they had underwent surgery for a submandibular carcinoma.

The **examination protocol** included the history of the patient, a brief physical examination, the salivation test and the US examination. The **history** focused on identifying the factors that could generate various, local or general, conditions of the salivary glands. The **salivation test** was based on the evaluation of the declared amount of salivation and on the quantitative assessment. The "Saliva - Check Buffer" (GC, Germany) test was used, which consisted of chewing paraffin wax for 5 minutes and continuously collecting the saliva in a graded container, followed by the calculation of the salivary flux expressed in ml/min. Values under 5 ml/min were considered normal.

US exploration. Two experienced examiners (ATS, RB) performed the US examinations. The ultrasound machine was Siemens S 2000 equipped with an 8-14 MHz linear transducer and adequate software for elastographic

examinations in SE, Strain Ratio Index (SRI), color-coded ARFI and quantitative ARFI mode. The patients were placed in decubitus with the head slightly extended. During the examination the patients breathed normally and avoided swallowing. First the grey-scale examination was performed, with 8 MHz transducer, using a single focus, placed on the submandibular gland. The perpendicular views, where the gland is visualized entirely, were used for the measurements of the sizes of the gland. The sizes of the submandibular glands were determined in 3 perpendicular axes: long, transverse and cranial-caudal view. The volume of the gland was calculated using the following formula: $Vol = (long\ diameter) \times (transverse\ diameter) \times (cranial-caudal\ diameter) \times 0.52$.

On the long view the gland has an oval shape, is elongated and limited by the skin and the oral roof. On the transverse view the submandibular gland is round and limited by the oral roof and skin. The Doppler exam, CFM mode, was used to emphasize the main parenchymal vessels. The long views, acquired in the long axis of the submandibular gland, where the gland was visualized entirely, with both the central and peripheral, subcapsular parenchyma visible, were considered valid for the assessment of the shear wave velocities measurements. The SWV measurements using the ARFI technique were performed by placing the predefined measurement sample in the centre of the gland as well as in the peripheral parenchyma. The values were expressed in m/s. The placement of the sample avoided the main vascular branches identified during the CFM exploration. The sample was placed at a depth of 1-1.5 cm and each measurement was registered in a database (fig 1, fig 2).

Statistical analysis. A mean value (M) and a standard deviation (SD) of the SWV values measured in the central (C) and peripheral (P) parenchyma of the SMG were calculated. Through the concatenation of the SWV values determined through the ARFI technique in the centre and in the periphery, the global M

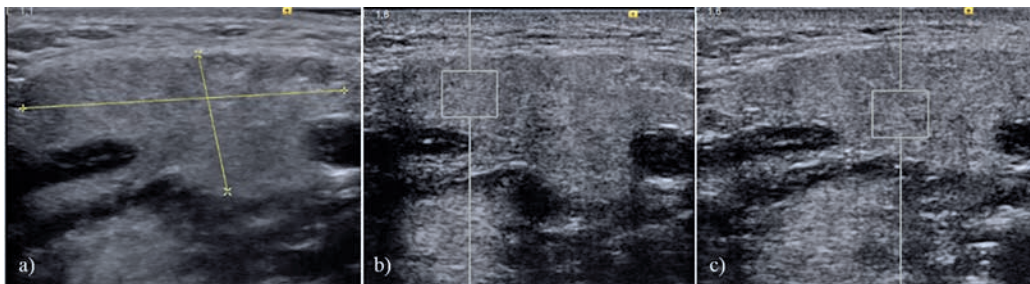


Fig 1. The examination of a patient from group A, left submandibular gland: a) B mode evaluation, b) SWV measurement within the peripheral parenchyma using the ARFI technique, c) SWV measurement within the central parenchyma using the ARFI technique.

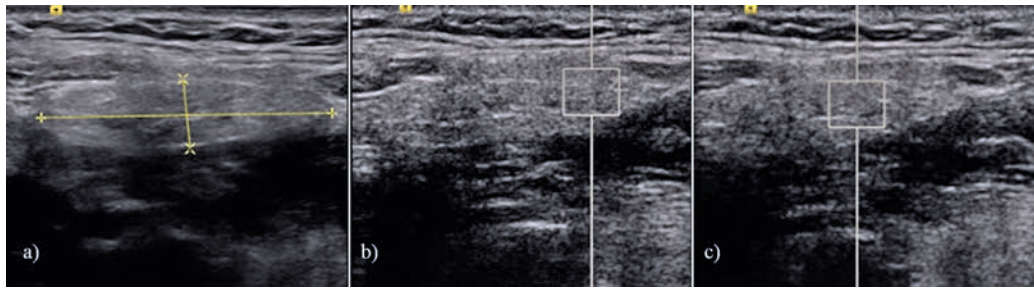


Fig 2. The examination of a patient from group B, right submandibular gland: a) B mode evaluation, b) SWV measurement within the peripheral parenchyma using the ARFI technique, c) SWV measurement within the central parenchyma using the ARFI technique.

Table I. The mean and standard deviation values of the shear wave velocities determined through the ARFI technique at the regions of interest.

	Left SMG			Right SMG		
	C	P	Global	C	P	Global
Group A						
M (m/s) ± SD	1,68 ± 0,46	1,88 ± 0,4	1,79 ± 0,33	1,74 ± 0,35	1,84 ± 0,43	1.82 ± 0,41
Group B						
M (m/s) ± SD	2,24 ± 0,49	2,10 ± 0,58	2,17 ± 0,46	1,99 ± 0,50	2,21 ± 0,52	2,13 ± 0,52

C-central parenchyma, P-peripheral parenchyma, Global-the mean of the concatenated of the C and P values, SMG-submandibular gland.

value and the corresponding SD were calculated for the left as well as for the right SMG. By the concatenation of all the SWV measurements obtained for group A, the M and SD for healthy patients were calculated (M group A). In a similar manner the M and SD were calculated for the patients that had undergone radiation therapy (M group B). The Microsoft Excel 2010 (Microsoft) software and Prism (GraphPad) were used in the analysis. The T two tailed test with n-2 degrees of freedom was used to compare mean values and the level of statistical significance was established at p=0.05.

Results

Following the described protocol a number of 1380 examinations were performed using the ARFI technique, 720 for group A and 660 for group B. The success rate of the SWV measurements using the ARFI technique was 100 %. The mean time necessary for an examination was 18.3 +/- 3.5 min. The results of the measurements for the two groups are presented in Table I.

No significant differences (p>0.05) between M C and M P corresponding to the left SMG as well as to the right SMG were found. Additionally there were no statistically significant differences (p>0.05) between the M C of the left and right SMG and between the M P of the left SMG versus the right SMG regardless of the group.

The comparative evaluation of the global M values inside group A and inside group B was not statistically relevant (p>0.05).

An evaluation of the mean of all the measurements in group A (M group A) versus the mean of all the measurements in group B (M group B) was realized by comparing the two groups (see graphic). The following results were obtained: M group A=1.82 ± 0.41 (m/s) and M group B= 2.13 ± 0.52 (m/s) (fig 3). The difference between these mean values was statistically significant (p<0.05).

By analyzing the volumes of all the glands from the healthy subjects compared with those of the patients that received radiation therapy a statistically significant difference was noticed in favor of the first group (7.97 ± 2.63 cm³ vs. 5.94 ± 4.16 cm³, p<0.05).

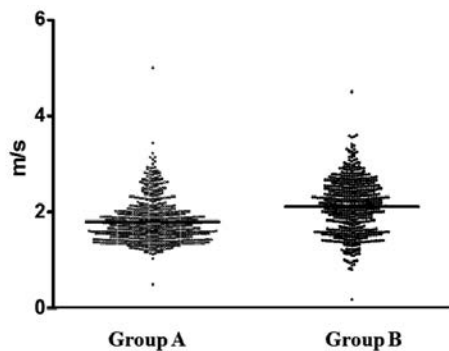


Fig 3. The measurements of the shear wave velocities determined using the ARFI technique for each group. The horizontal line is placed at the level of the mean value.

Discussions

US is a widespread diagnosis method with several qualities worthy of consideration: accessibility, dynamic imaging (“real-time”), innocuity, agreeable to patients, and accuracy. For a very long time, US was considered to be a strictly anatomical exploration. Empirical observations have shown the potential of this method in appreciating the compliance of the organ parenchyma, demonstrated on the real-time image through a firm compression with the transducer. In the last 10-15 years there have been many technological developments, the most spectacular being focused on the use of contrast media and elastography, both having a proven value in clinical practice.

Elaborate studies have shown that there is a possibility to directly evaluate the elasticity of the tissues. The reflecting elements found in the structure of the biological tissues, a good enough penetration at high frequencies of the ultrasound beam (and implicitly a very good resolution) and the high transmission velocity of US in tissues represent factors that allow “real-time” elastographies of the superficial organs (currently known as “small parts”) [5,14].

An elastographic procedure, recently introduced into practice, is the one based on the existence of the shear waves within the tissue that are exposed to an US beam with intermittent (TE) or continuous emission (SWE, ARFI) [15]. The shear waves represent movement waves perpendicular on the axis of the US beam generated by the transducer, with frequencies and velocities lower than those of the beam. They do not interfere with the grey scale image, thus making them invisible. The shear wave velocity directly correlates with tissue stiffness, being

higher when the tissue is stiffer and lower when the tissue is elastic. The elastographic procedures based on the shear wave are quantitative and reproducible. The information that is obtained is expressed either color-coded either in kPa or in m/sec.

It has been demonstrated that elastography which is based on the shear waves allows a better discrimination of the nodules found in full, superficial organs [16]. Therefore, in the case of the thyroid, values > 65 kPa detected in the nodules are highly suggestive for a malignant nature [10]. It is assumed that the same performance can be obtained in the case of the salivary glands. Unfortunately there are studies showing that the complex morphology of the salivary tumors decreases the performance of SWE. For example the pleomorphic adenoma of the parotid glands has a stiffness of 22.5 kPa with the extremes between 9.7 and 59.4 kPa, while the Whartin tumor has values around 16.9 kPa (with an interval between 3.8-47.8 kPa) [14]. These large intervals of the stiffness values make the method of little value for clinical practice. But because the ARFI values of the velocities within the tumors are different from those identified in the parenchyma, it can be considered that the SWE has a value in consolidating the diagnosis of tumor. Additionally, the method allows the evaluation of the normal parenchyma elasticity. For the submandibular glands this is between 5.6 - 16.2 kPa, with a mean value of 11.3 kPa and a standard deviation of ± 1.4 kPa [14].

Among the SMG conditions the iatrogenic conditions is a special category generally with diffuse character. Radiotherapy performed for cervical and facial oncological conditions determines irreversible alterations of the salivary glands by generating an initial acute inflammatory reaction, followed by a chronic hypotrophy [16]. Each year 350,000 patients are exposed to radiation for therapeutic purposes. About 80% of these patients develop a decrease of salivation and as a result a serious alteration of the quality of their lives with exposure to infections of the oral cavity, tooth cavities, dysphagia, and pain [17]. There are some prophylactic solutions for such situations, but their results are questionable, that is why an early diagnosis of the condition is so important [18].

The elastographic examination of the salivary glands is known mainly as a diagnosis method useful for the consolidation of the diagnosis of a tumor. The application of this method in diffuse conditions is less discussed in literature. There are inconsistent data that show the relevance of ARFI images in cases of submaxillities by the fractal analysis of the images [19]. We did not find in literature applications on larger groups of patients. This is a paradox considering the lack of objective instruments for the evaluation of the diffuse diseases of the subman-

dibular glands. Generally, the diagnosis is based on the palpation of the gland, performed by the clinician, which leaves the final conclusion to a certain dose of subjectivity being conditioned by the experience of the examiner. Furthermore the evolution/involution of a certain diffuse condition can only be appreciated using functional tests. The use of biopsies is not so popular and is disagreeable. Additionally, there are no methods to detect the diffuse conditions in early phases.

The present study shows that elastography using ARFI technique can fill this void in clinical practice. A trustworthy application of the method requires the knowledge of the normal values, a clear method of examination, the establishment of the success rate and the validation of the method in a significant manner.

Until now the literature does not record any data regarding the values of the shear wave velocities of the normal or post radiation submandibular glands.

Mansour et al [20] realized the only similar study on the submandibular glands (emphasis on the parotid gland). We consider that the present study represents a beginning for the consolidation of the literature that focuses on the value of the ARFI data in the circumstances we just talked about. The normal values of the shear wave velocities of the submandibular gland parenchyma as they result from our study are around 1.82 m/sec. At the same time the study sustains an important result in the fact that the SWV determinations using ARFI are not dependent on placing the sample in the glandular parenchyma. The differences between the central and the peripheral areas are little and statistically insignificant. Another important conclusion refers to the similarity of the mean SWV between the left and right SMG in normal subjects. In order to consolidate this information a further phase of the study will follow and the group of patients will be extended, both in number as well as in age distribution.

The age of the patients is one of the limits of this study. Even though a large age spectrum was evaluated (19-67 years old) this should be extended, especially by including patients over 67 years old. This statement is based on the changes suffered with age by the glandular parenchyma (an increase of the volume occupied by adipocytes and connective tissue) which might influence the establishment of the normal ARFI measurements on age groups [21].

The examination method is easy and very well tolerated by the patient. From our experience, but also from the literature data, the result is that it is recommended to perform several measurements and calculate a mean value for credible results. The success rate in acquiring information is very high (as much as 100%), making the method a valid one. The operator dependent character of the examination, even though it was not statistically

evaluated in this study, is lower than in the case of a “real time”, color-coded elastography.

The quantification of the operator dependence character and the establishment of the intra/interobserver consensus are regarded as limits of the study and will be further evaluated in the future. The time necessary for the examination was relatively short, but a comparison with other literature data on this topic was not possible since there is no research regarding this at the moment. We consider that these intervals will be improved in the case of our examiners due to the acquired experience. At the same time, since there are no differences between the values obtained in the centre and in the periphery of the gland, in the future the examination will be limited to the most accessible region. As a result of these factors the time of examination will decrease.

The SWV measurements using ARFI performed on patients who received radiation therapy may represent a clinical application of the procedure. After radiation the SMG suffer a process of inflammation followed by fibrosis and functional consequences [22]. These changes set in very quickly after the initiation of the therapy. In the present study, the mean value of the SWV identified in the group B subjects is 2.13 m/sec, significantly different from that found in group A. But as in group A, the velocities were not significantly different between the centre and the periphery, or between the glands evaluated as a whole. The demonstration of these changes places ARFI elastography as a routine examination of these patients. We consider that the method can be used for the evaluation of the efficiency of the recuperation therapy of the parenchyma, but this requires further studies.

The advantages of the ARFI technique are represented by the quantitative character of the procedure, the measurements being expressed in m/sec. The acquisition sample can be easily moved along the regions of interest of the gland, thus increasing the versatility of the method. The technique has a real potential in establishing the trend of the disease and in consolidating the clinical diagnosis.

The sensitivity of the method related to the early changes of the parenchyma is not yet known, further studies being necessary. It is expected that the ARFI changes are independent from the etiopatogenesis of the process. This is explained by the fact that the method quantifies and evaluates tissue stiffness, which is present in various histological diseases such as the lymphoplasmacytic inflammatory infiltrate but also in fibrosis. As happened in our study, the reduced volume of the gland pleads for the presence of fibrosis. In our opinion it is necessary to integrate the information that was obtained by applying ARFI in an algorithm that comprises additional criteria (size, structure, vascularity). In that way we aspire towards a

noninvasive diagnosis of diffuse conditions. Obviously, from this point of view it is also necessary to extend the study on a larger group of patients with various, well documented diseases, even morphologically if possible.

Conclusions

The ARFI examination of the SMG represents an objective modality for the evaluation of parenchyma stiffness in normal and pathological situations. The mean value of the SWV corresponding to normal stiffness, determined through the ARFI technique, is similar in the two glands, measuring 1.82 m/sec. In the post radiation therapy group, the values of the SWV, determined through the ARFI technique, correspond to an increased stiffness, with a mean value of 2.13 m/sec.

Conflict of interest: none

Acknowledgements. We express our gratitude to Ms Zsako Sasz and Claudia Coroiu for their support in enrolling the patients. We also want to thank Dr. Monica Lușor Platon for her assistance in realizing the design of the research. The present study is financed through the PODS-DRU no. 88/1.5/S/56949 doctoral scholarship project.

References

- Goh YH, Sethi DS. Submandibular gland excision: a five-year review. *J Laryngol Otol* 1998; 112: 269-273.
- Bialek EJ, Jakubowski W, Zajkowski P, Szopinski KT, Osmolski A. US of the Major Salivary Glands: Anatomy and Spatial Relationships, Pathologic Conditions, and Pitfalls. *Radiographics* 2006; 26: 745-763.
- Gallipoli A, Manganella M, De Lutiodi Di Castalguidone E, et al. Ultrasound contrast media in the study of salivary gland tumors. *Anticancer Res* 2005; 25: 2477-2482.
- Doherty JR, Trahey GE, Nightingale KR, Palmeri ML. Acoustic radiation force elasticity imaging in diagnostic ultrasound. *IEEE Trans Ultrason Ferroelectr Freq Control* 2013; 60: 685-701.
- Bamber J, Cosgrove D, Dietrich CF, et al. EFSUMB guidelines and recommendations on the clinical use of ultrasound elastography. Part 1: Basic principles and technology. *Ultraschall Med* 2013; 34: 169-184.
- Itoh A, Ueno E, Tohno E, et al. Breast disease: clinical application of US elastography for diagnosis. *Radiology* 2006; 239: 341-350.
- Bojunga J, Herrmann E, Meyer G, Weber S, Zeuzem S, Friedrich-Rust M. Real-time elastography for the differentiation of benign and malignant thyroid nodules: a meta-analysis. *Thyroid* 2010; 20: 1145-1150.
- Lușor M, Badea R, Ștefănescu H, et al. Analysis of histopathological changes that influence liver stiffness in chronic hepatitis C. Results from a cohort of 324 patients. *J Gastrointest Liver Dis* 2008; 17: 155-163.
- Tanter M, Bercoff J, Athanasiou A, et al. Quantitative assessment of breast lesion viscoelasticity: initial clinical results using supersonic shear imaging. *Ultrasound Med Biol* 2008; 34: 1373-1386.
- Sebag F, Vaillant-Lombard J, Berbis J, et al. Shear wave elastography: a new ultrasound imaging mode for the differential diagnosis of benign and malignant thyroid nodules. *J Clin Endocrinol Metab* 2010; 95: 5281-5288.
- Westerland O, Howlett D. Sonoelastography techniques in the evaluation and diagnosis of parotid neoplasms. *Eur Radiol* 2012; 22: 966-969.
- Dumitriu D, Ducea SM, Botar-Jid C, Băciuț G. Ultrasonographic and sonoelastographic features of pleomorphic adenomas of the salivary glands. *Med Ultrason* 2010; 12: 175-183.
- Lușor M, Badea R, Ștefănescu H, et al. Performance of a new elastographic method (ARFI technology) compared to unidimensional transient elastography in the noninvasive assessment of chronic hepatitis C. Preliminary results. *J Gastrointest Liver Dis* 2009; 18: 303-310.
- Bhatia KS, Rasalkar DD, Lee YP, et al. Evaluation of real-time qualitative sonoelastography of focal lesions in the parotid and submandibular glands: applications and limitations. *Eur Radiol* 2010; 20: 1958-1964.
- Gennisson JL, Deffieux T, Fink M, Tanter M. Ultrasound elastography: Principles and techniques. *Diagn Interv Imaging* 2013; 94: 487-495.
- Epstein JB, Thariat J, Bensadoun RJ, et al. Oral complications of cancer and cancer therapy: from cancer treatment to survivorship. *CA Cancer J Clin* 2012; 62: 400-422.
- Jemal A, Siegel R, Ward E, Murray T, Xu J, Thun MJ. Cancer statistics, 2007. *CA Cancer J Clin* 2007; 57: 43-66.
- Cotrim AP, Hyodo F, Matsumoto K, et al. Differential radiation protection of salivary glands versus tumor by tempol with accompanying tissue assessment of tempol by magnetic resonance imaging. *Clin Cancer Res* 2007; 13: 4928-4933.
- Badea AF, Lușor Platon M, Crișan M, et al. Fractal analysis of elastographic images for automatic detection of diffuse diseases of salivary glands: preliminary results. *Comput Math Methods Med* 2013; 2013: 347238.
- Mansour N, Stock KF, Chaker A, Bas M, Knopf A. Evaluation of parotid gland lesions with standard ultrasound, color duplex sonography, sonoelastography, and acoustic radiation force impulse imaging - a pilot study. *Ultraschall Med* 2012; 33: 283-288.
- Rother P, Peil J, Schmerling S, Mahn G, Böttger O. Morphometric studies of the aging of human submaxillary glands (author's transl). *Anat Anz* 1982; 151: 29-40.
- Grundmann O, Mitchell GC, Limesand KH. Sensitivity of salivary glands to radiation: from animal models to therapies. *J Dent Res* 2009; 88: 894-903.