Medical Ultrasonography
2012, Vol. 14, no. 3, 235-238

Ultrasound-guided injections in the middle and lower cervical spine

Alexander Loizides[1], Jochen Obernauer[2], Siegfried Peer[1], Reto Bale[1], Klaus Galiano[2], Hannes Gruber[1]

[1] Department of Radiology, [2] Department of Neurosurgery, Innsbruck Medical University, Innsbruck, Austria

Abstract

Injection therapies play a major role in the treatment of cervical pain and are becoming integral parts of a multidisciplinary approach in treatment and rehabilitation of such patients. Pararadicular- and facet-joint injections in the cervical spine are preferentially performed under computed tomography (CT) or fluoroscopy-guidance. In this article we present an alternative, simple and easy to learn step by step US-guided technique for injection therapy in the cervical spine.

Keywords: ultrasound guidance, pararadicular injection, facet-joint injection.

Introduction

Cervical pain is a common entity in clinical practice - at least transient cervical radiculopathy occurs in almost 40% of the population at some time during their lives [1,2]. Aside from physical therapy and other rehabilitative methods, injection therapy targeted to the facet joints or to the nerve roots is well established in the treatment of cervical radiculopathy and is indicated when exclusive conservative treatment fails. In cases of clear neurologic deficit or associated myelopathic signs, surgical intervention is recommended [3]. Imaging guidance has increased the precision of spinal injection and computed tomography (CT) or fluoroscopy are to date preferentially used [4-7]. Ultrasound (US) had proven at least sufficiently reliable and accurate in the demonstration of cervical paravertebral anatomy [8-14] . The feasibility of US-guided injection therapy at the spine was also demonstrated in several studies [8-11,15-18].

Received 11.05.2012 Accepted 25.05.2012
Med Ultrason
2012, Vol. 14, No 3, 235-238
Corresponding author: Alexander Loizides, MD
Innsbruck Medical University,
Department of Radiology
Anichstrasse 35, 6020 Innsbruck, Austria
Tel: +43/512/504/22761
Fax: +43/512/504/22758
E-mail: alexander.loizides@i-med.ac.at

Indications

Indications for injection therapy of cervical roots are borderline lateral and intraforaminal disc herniations and chronic nerve irritation by inoperable bone changes. For the cervical facet joints indications are acute facet joint impairment due to microtrauma and instability and facet joint osteoarthritis including facet joint hyperplasia.

US-guided injections

The pararadicular injections in the cervical spine are performed with the patient in a prone position and the head of the patient turned to the affected side. These US injections may be performed on a standard ultrasound device using a 12-5 MHz broadband linear array transducer. The whole procedure is done under sterile conditions: the patient is cleansed and covered with sterile drapes, the ultrasound transducer is placed in a sterile sheath and sterile ultrasound gel is used.

Techniques of US-guided pararadicular injections:

Three transverse scans are performed stepwise to define the necessary anatomical landmarks in order to perform topographically correct injections as follows:

1) In an exact midline axial scan the spinous processes of the lower cervical spine are defined (fig 1).

2) From this midline position the transducer is offset laterally along the vertebral arch and the respective ar-

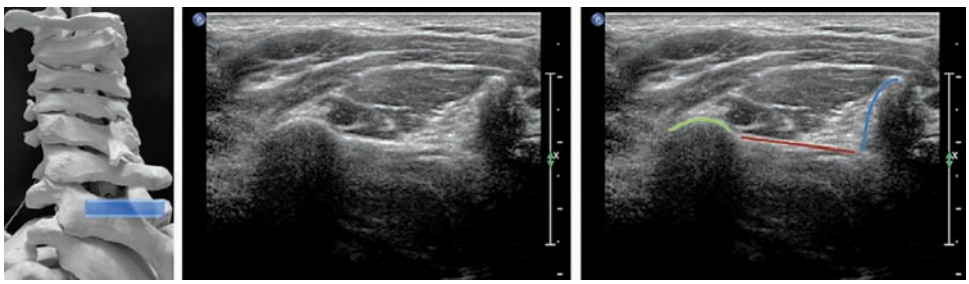

Fig 1. Posterior axial scan plane of the spinous process (blue) at the level of C7 left. Vertebral arch: violett, articular process: light green.

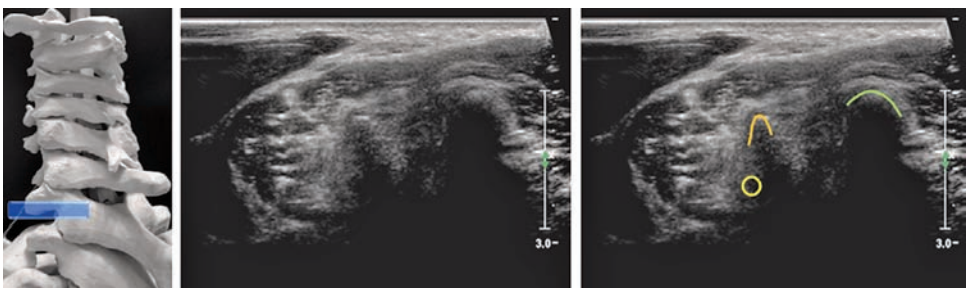

Fig 2. Posterior axial scan plane of the transverse process at the level C7 left. Note the missing anterior tubercle. Articular process: light green, posterior tubercle: orange, C7 nerve root: yellow.

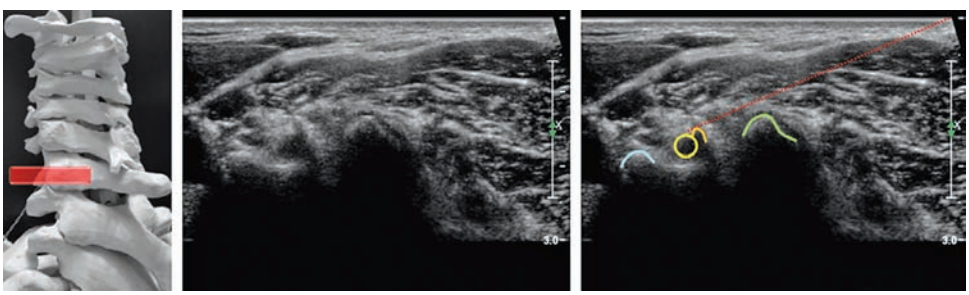

Fig 3. Posterior transverse scan plane of the transverse process at the level C6 left. Articular process: light green, posterior tubercle: orange, anterior tubercle: light blue, C6 nerve root: yellow, intended needle path: red.

ticular process towards the transverse process. The transverse process of the C7 vertebra is defined as follows: the missing anterior tubercle defines the C7 vertebra as it is the only cervical vertebra with a missing anterior tubercle (fig 2). After the definition of this landmark the transducer is moved further laterally to the respective root and cephalad to the respective level by counting of the transverse processes.

3) In this final scan plane the spinal nerves can clearly be identified as hypoechoic round-to-oval structures always exiting the cervical spine ventral to the posterior tubercle of the transverse processes.

After the correct scan plane for the intended intervention is reached a 20 G spinal needle is advanced from a dorsomedial approach towards the dorsal aspect of the spinal nerve under real-time US guidance (fig 3): the needle is inserted using a free-hand-in-plane puncture technique. In this technique the needle is advanced strictly parallel to the long axis of the transducer to advance it within the scanning plane, which was originally developed and described for the psoas compartment block [19]. After placement of the needle, 1 ml of a corticosteroid solution (e.g. betamethasone 4 mg/ml) is injected in the immediate pararadicular compartment, which is ensured by a periradicular fluid-spread in US.

Techniques of US-guided facet joint injections:

Beginning in an axial transducer orientation along the spinous processes, the C7 landmark is defined according

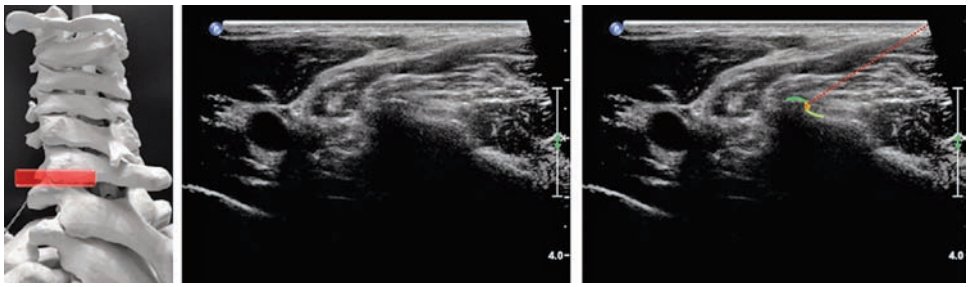

Fig 4. Posterior axial scan plane of the left facet-joint C6/7 (joint space: light brown). Superior articular process (C7): light green, inferior articular process (C6): dark green, intended needle path: red.

to the procedure specified above: after the respective cervical segment is defined, the transducer is centred over the according articular process. By slightly tilting and pivoting of the transducer in this axial position the respective facet joint becomes visible. Subsequently a 20 G spinal needle is inserted from a dorsomedial approach in in-plane-technique (see above) which enables for a visualization of the complete needle path in real-time (fig 4). After the needle tip reaches the respective facet joint (intraarticular bone contact) 1 ml of an even mixture of 0.5 % bupivacaine hydrochloride and of betamethasone (4 mg/ml), is administered intra-articularly (until resistance is encountered) and the remainder of the dose is administered around the respective facet joint capsule.

Summary

Imaging guided pararadicular and facet joint injections are to date mainly performed under CT or fluoroscopic guidance. US is already used successfully to guide a variety of instillation procedures in different anatomical regions showing many benefits: direct visualization of the target of interest, real-time needle guidance, visualization of the spread of local anaesthetics and thus minimal risk of complications, a potential for dose reduction of local therapeutics, shortening of procedure time and the lacking of exposure to ionizing radiation [8-11,15-18]. The above described new approaches are reliable, safe and accurate in therapeutic needle placement for pararadicular and facet joint injections in the middle and lower cervical spine.

References

1. Smith MD. Cervical radiculopathy: causes and surgical treatment. Minn Med 1995; 78: 28-30, 42-45.
2. Cyteval C, Thomas E, Decoux E, et al. Cervical radiculopathy: open study on percutaneous periradicular foraminal steroid infiltration performed under CT control in 30 patients. AJNR Am J Neuroradiol 2004; 25: 441-445.
3. Ellenberg MR, Honet JC, Treanor WJ. Cervical radiculopathy. Arch Phys Med Rehabil 1994; 75: 342-352.
4. Derby R, Kine G, Saal JA, et al. Response to steroid and duration of radicular pain as predictors of surgical outcome. Spine (Phila Pa 1976) 1992; 17(6 Suppl): S176-183.
5. Gangi A, Dietemann JL, Mortazavi R, Pfleger D, Kauff C, Roy C. CT-guided interventional procedures for pain management in the lumbosacral spine. Radiographics 1998; 18: 621-633.
6. Fritz J, Niemeyer T, Clasen S, et al. Management of chronic low back pain: rationales, principles, and targets of imaging-guided spinal injections. Radiographics 2007; 27: 1751-1771.
7. Silbergleit R, Mehta BA, Sanders WP, Talati SJ. Imaging-guided injection techniques with fluoroscopy and CT for spinal pain management. Radiographics 2001; 21: 927-939.
8. Galiano K, Obwegeser AA, Walch C, Schatzer R, Ploner F, Gruber H. Ultrasound-guided versus computed tomography-controlled facet joint injections in the lumbar spine: a prospective randomized clinical trial. Reg Anesth Pain Med 2007; 32: 317-322.
9. Galiano K, Obwegeser AA, Bale R, et al. Ultrasound-guided and CT-navigation-assisted periradicular and facet joint injections in the lumbar and cervical spine: a new teaching tool to recognize the sonoanatomic pattern. Reg Anesth Pain Med 2007; 32: 254-257.
10. Galiano K, Obwegeser AA, Bodner G, et al. Ultrasound guidance for facet joint injections in the lumbar spine: a computed tomography-controlled feasibility study. Anesth Analg 2005; 101: 579-583.
11. Galiano K, Obwegeser AA, Bodner G, et al. Real-time sonographic imaging for periradicular injections in the lumbar spine: a sonographic anatomic study of a new technique. J Ultrasound Med 2005; 24: 33-38.
12. Kirchmair L, Entner T, Wissel J, Moriggl B, Kapral S, Mitterschiffthaler G. A study of the paravertebral anatomy for ultrasound-guided posterior lumbar plexus block. Anesth Analg 2001; 93: 477-481.
13. Loizides A, Peer S, Plaikner M, et al. Ultrasound-guided injections in the lumbar spine. Med Ultrason 2011; 13: 54-58.

14. Loizides A, Gruber H, Peer S, Brenner E, Galiano K, Obernauer J. A new simplified sonographic approach for pararadicular injections in the lumbar spine: a CT-controlled cadaver study. AJNR Am J Neuroradiol 2011; 32: 828-831.
15. Galiano K, Obwegeser AA, Bodner G, et al. Ultrasound-guided facet joint injections in the middle to lower cervical spine: a CT-controlled sonoanatomic study. Clin J Pain 2006; 22: 538-543.
16. Galiano K, Obwegeser AA, Bodner G, Freund MC, Gruber H, Maurer H et al. Ultrasound-guided periradicular injections in the middle to lower cervical spine: an imaging study of a new approach. Reg Anesth Pain Med 2005; 30: 391-396.
17. Greher M, Scharbert G, Kamolz LP, et al. Ultrasound-guided lumbar facet nerve block: a sonoanatomic study of a new methodologic approach. Anesthesiology 2004; 100: 1242-1248.
18. Kapral S, Krafft P, Eibenberger K, Fitzgerald R, Gosch M, Weinstabl C. Ultrasound-guided supraclavicular approach for regional anesthesia of the brachial plexus. Anesth Analg 1994; 78: 507-513.
19. Kirchmair L, Entner T, Kapral S, Mitterschiffthaler G. Ultrasound guidance for the psoas compartment block: an imaging study. Anesth Analg 2002; 94: 706-710.