Pictorial essay

Medical Ultrasonography
2011, Vol. 13, no. 2, 150-156

Contrast enhanced ultrasound of kidneys. Pictorial essay

Ashutosh Prakash, Gerald Jit Shen Tan, Gervais Khin-Lin Wansaicheong

Diagnostic Radiology, Tan Tock Seng Hospital, Singapore

Abstract

Contrast-enhanced ultrasound has entered the imaging mainstream in the last few years. It is a safe technique with exquisite temporal and spatial resolution and is especially useful for evaluating focal renal mass lesions in patients with renal impairment when iodinated or gadolinium contrast agents are contraindicated. The purpose of this manuscript is to briefly describe our technique, show the normal renal haemodynamics of ultrasound contrast agent and demonstrate a spectrum of renal masses and possible pitfalls.

Keywords: ultrasonography, renal masses, contrast enhancement, microbubbles

Rezumat

In ultimii ani ecografia cu substanță de contrast a devenit o tenhică imagistică cu tot mai largi întrebuințări. Este o tehnică cu un nivel de siguranță crescut, având totodată rezoluție temporal şi spațială foarte bună. Una dintre cele mai utile indicații este evaluarea maselor tumorale la pacienții a căror funcție renală este alterată, aceştia având contraindicată utilizarea agenților de contrast iodinați sau cu gadolinium. Scopul acestui eseu în imagini este de a descrie pe scurt tehnica folosită de noi, a demonstra hemodinamica agenților de contrast, a exemplifica aspectul prinipalelor tumori renale precum şi a posibilelor capcane ecografice

Cuvinte cheie: ecografia, tumori renale, agenți de contrast, microbule

Introduction

Ultrasound is the standard method for first intentional evaluation of kidney. Differentiation between renal cysts and mixed solid tumours is sometimes difficult with conventional and Doppler sonography, and has traditionally being done by contrast enhanced computed tomography (CT) and magnetic resonance imaging (MRI). This can now also be done by contrast enhanced ultrasonography (CEUS). Ultrasound contrast media are not nephrotoxic and can be safely used in patients with renal impairment [1].

The pictorial is structured into: normal physiology of ultrasound contrast agent in the kidney, cystic masses, solid masses and normal variants that mimic a renal mass.

Technique

The CEUS images in this paper were obtained by using sulphur hexafluoride (SF_6) microbubbles (Bracco Imaging, Milan, Italy) as the ultrasound contrast agent. This blood pool agent is excreted by exhalation through the lungs and does not interfere with renal or hepatic excretion. The main contraindications are recent acute myocardial infarction (< 7 days), class III / IV cardiac failure, right-to-left shunts, severe pulmonary hypertension, pregnancy and breastfeeding. We performed our studies using the Toshiba Aplio XG machine (Toshiba, Otawara, Japan) with convex abdominal volumetric transducer

Received 12.04.2011 Accepted 30.04.2011
Med Ultrason
2011, Vol. 13, No 2, 150-156
Address for correspondence: Dr. Ashutosh Prakash
Diagnostic Radiology
Tan Tock Seng Hospital
11 Jalan Tan Tock Seng
SINGAPORE 308433
E-mail: drashutoshprakash@gmail.com
Fax number: (+65) 63578113
Telephone: (+65) 81278642

(1.5-7 MHz, 3.75-MHz centre frequency). Following intravenous bolus injection of 2.4 ml of contrast agent, images were acquired using contrast harmonic imaging (CHI) and stored as cine clips as well as a volume dataset over a span of three minutes.

While doing the CEUS in our institute we spilt the monitor into two-image display, with contrast only subtracted image displayed on the left and grey scale image displayed on the right. All the CEUS images in this paper are shown in the same way and readers are advised to remember this to avoid confusion while seeing the images.

Physiology of ultrasound contrast agent in the kidney

The kidneys have a single-phase arterial supply, allowing for rapid contrast enhancement and assessment following contrast administration. The normal kidney enhances in the following fashion:

a) Early arterial phase: renal arteries are well-demonstrated (fig 1).

b) Late arterial or cortical phase: intense and uniform enhancement of the renal cortex (fig 2).

c) Medullary phase: pyramids gradually fill with contrast until they are isoechoic with the cortex (fig 3).

Unlike iodinated contrast media, CEUS microbubbles are blood pool agents and there is no pyelographic phase.

Cystic masses

There is over all 39% and more than 50% incidence of renal cyst in patients older than 50 years of age [2]. Most of these cysts are incidentally detected. We use the Bosniak classification system to evaluate cystic renal mass lesions [3]. CEUS has the ability to resolve small tumoral vessels and is appropriate for renal cyst classification with the Bosniak System [4]. Bosniak classification suggests malignant potential of a cystic mass, detail of which is beyond the scope of this manuscript and reader are advised to read it. Surgery is recommended for IV and III categories, category IIF requires follow-up to show stability over time and category II and I are benign. Figures 4 to 7 show examples of Bosniak category I, II, IIF and III cysts. Figure 8 shows renal abscess in a patient with urinary tract infection.

Solid masses

Internal echoes with a cyst can be dense and does not always demonstrate layering on grey scale imaging and can therefore mimic a solid tumour on grey scale ultra-

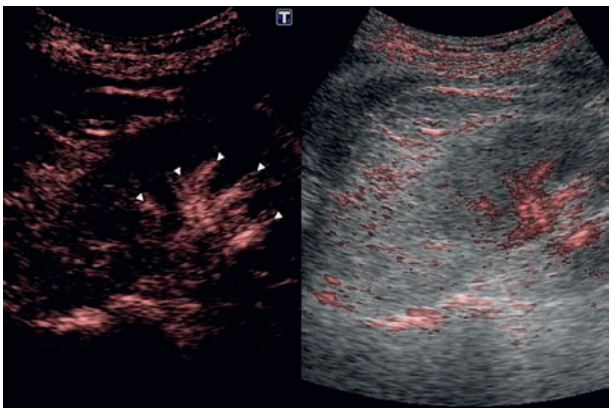

Fig 1. Early arterial phase CEUS. Contrast-only subtracted image on the left and contrast overlaid on grey scale image on the right, taken 11 seconds after contrast injection, demonstrates enhancement of the intra-renal segmental arteries (arrowheads).

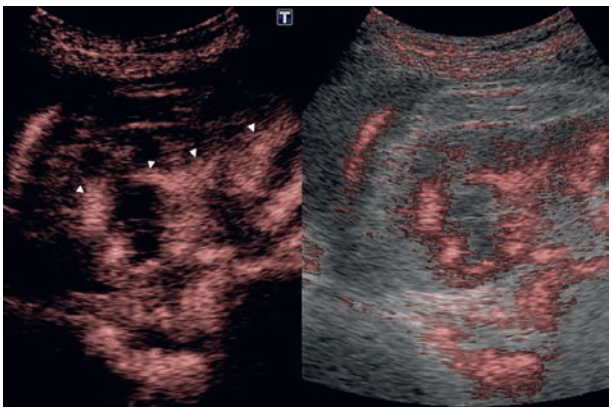

Fig 2. Late arterial phase CEUS. Images taken 14 seconds after contrast injection, demonstrates enhancement of renal cortex (arrowheads).

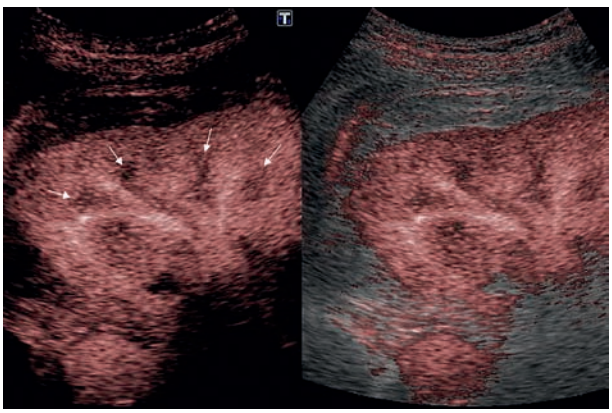

Fig 3. Medullary phase CEUS. Renal pyramids (arrows) slowly enhance and progressively fill-in between 20 seconds to 1 minute post-injection.

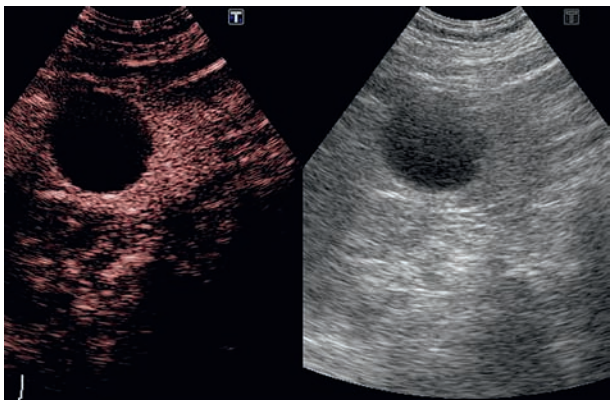

Fig 4. Bosniak category I cyst. CEUS image showing renal cyst with no calcification, septation or contrast enhancement.

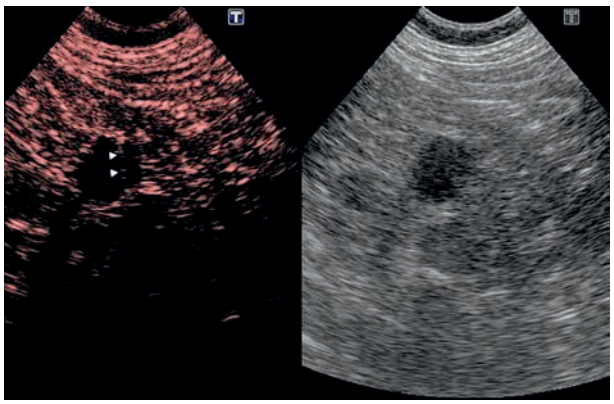

Fig 5. Bosniak category II cyst. CEUS image showing renal cyst with single mildly enhancing thin septa (arrowheads).

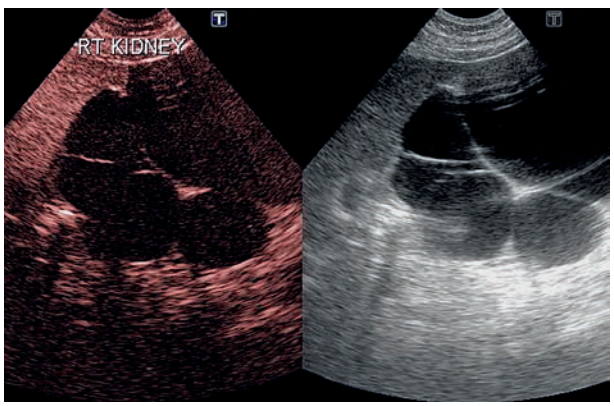

Fig 6. Bosniak category IIF cyst. CEUS image showing renal cyst with several enhancing thin septae.

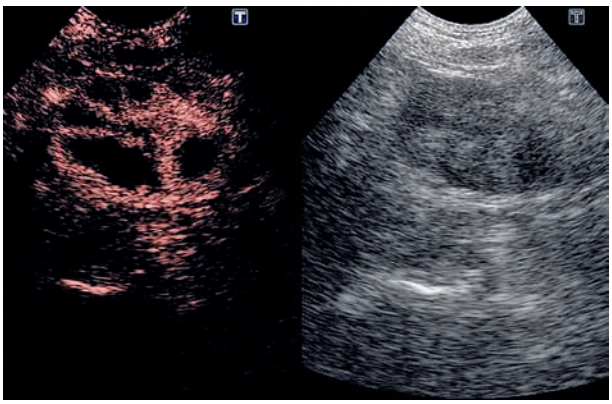

Fig 7. Bosniak category III cyst. CEUS image showing renal cyst with multiple enhancing thick septae.

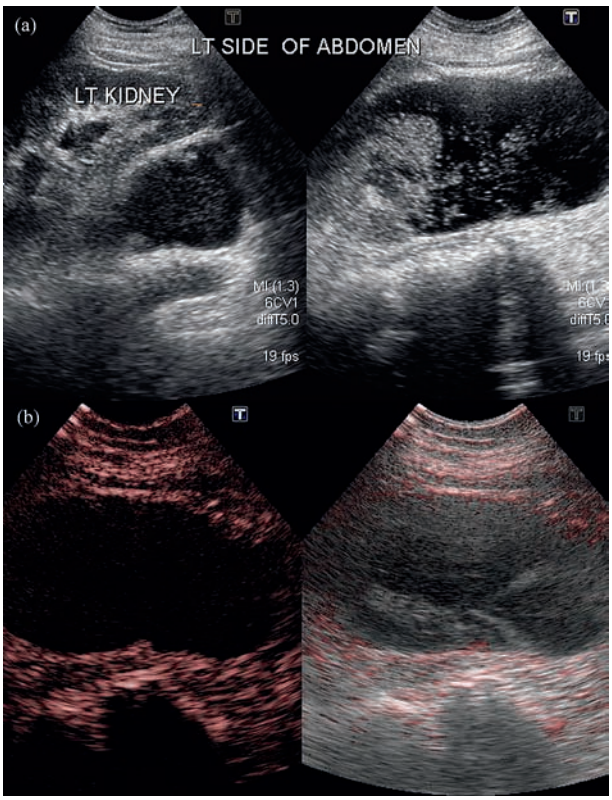

Fig 8. (a) Grey scale images showing cyst with internal echoes; (b) CEUS image, no contrast enhancement is seen with in the lesion. This patient had fever and urinary tract infection. Imaging and clinical findings were consistent with renal abscess; confirmed on percutaneous drainage.

sonography. CEUS can differentiate between the complicated cyst (fig 9) and solid tumour (fig 10).

Further role of imaging is to differentiate these solid renal masses into benign and malignant lesions. Imaging features of plain and contrast enhanced CT and MRI can be applied to CEUS for characterisation of solid renal masses [5]. The tumor echogenicity on grey scale, enhancement patterns, and degree of enhancement at different phases are used to differentiate benign and malignant solid renal mass lesions. Contrast-enhanced ultrasonography is valuable in differentiating angiomyolipoma (AML) and renal cell carcinoma (RCC) [6]. CEUS features of homogeneous and prolonged enhancement are suggestive of AML (fig 11); an early washout, heterogeneous enhancement, and an enhanced peritumoral rim or pseudocapsule highly suggest RCC (fig 12) [6,7,8]. CEUS can also be used to differentiate between tumour and brand IVC thrombus related to renal cell carcinoma (fig 13).

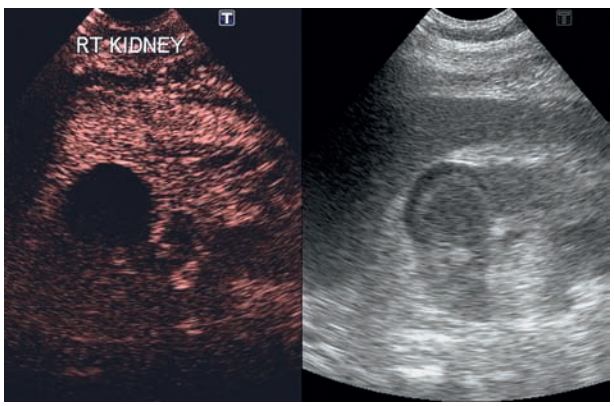

Fig 9. CEUS image; right upper pole cyst with dense echogenic component does not show contrast enhancement and is therefore a benign cyst with non-vascular debris or blood clot.

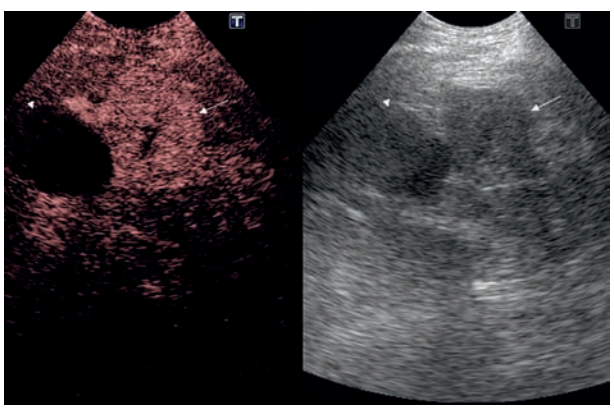

Fig 10. CEUS image; two cysts with internal echoes on grey scale ultrasonography. One lesion is uniformly non-enhancing and therefore benign (arrowheads). The other lesion demonstrates marked enhancement of the internal echoes consistent with solid tumour (arrow).

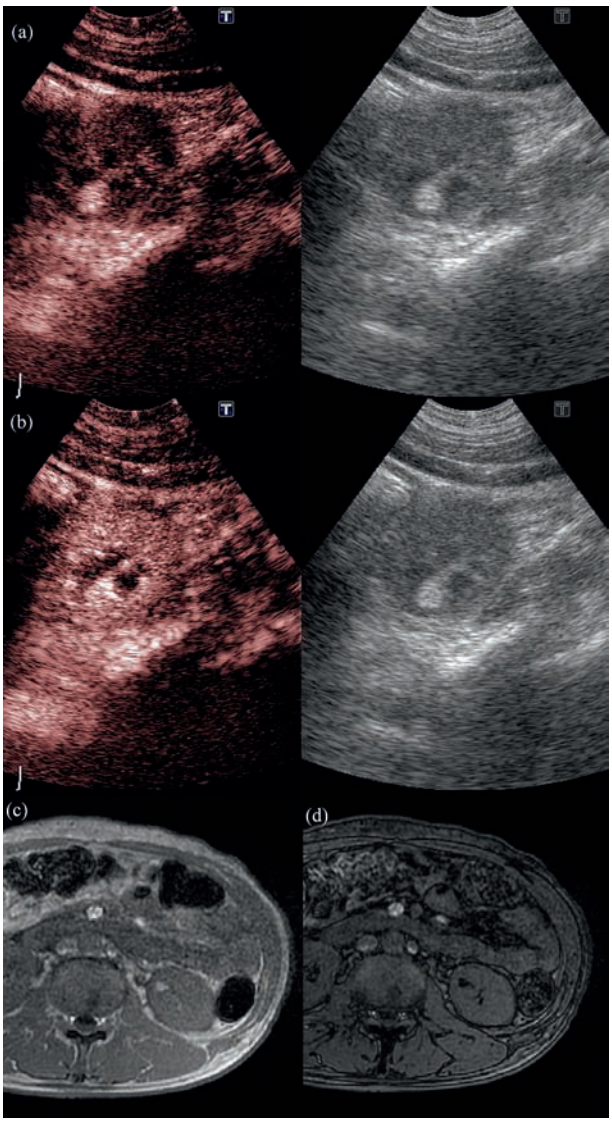

Fig 11. Angiomyolipoma: a) Well defined round hyperechoic renal lesion in left lower pole showing early contrast enhancement on CEUS; b) Enhancement persists in the late phase of CEUS;. c) In phase and (d) out of phase MRI images demonstrate signal drop off in out of phase image, this is in keeping with fat-containing angiomyolipoma.

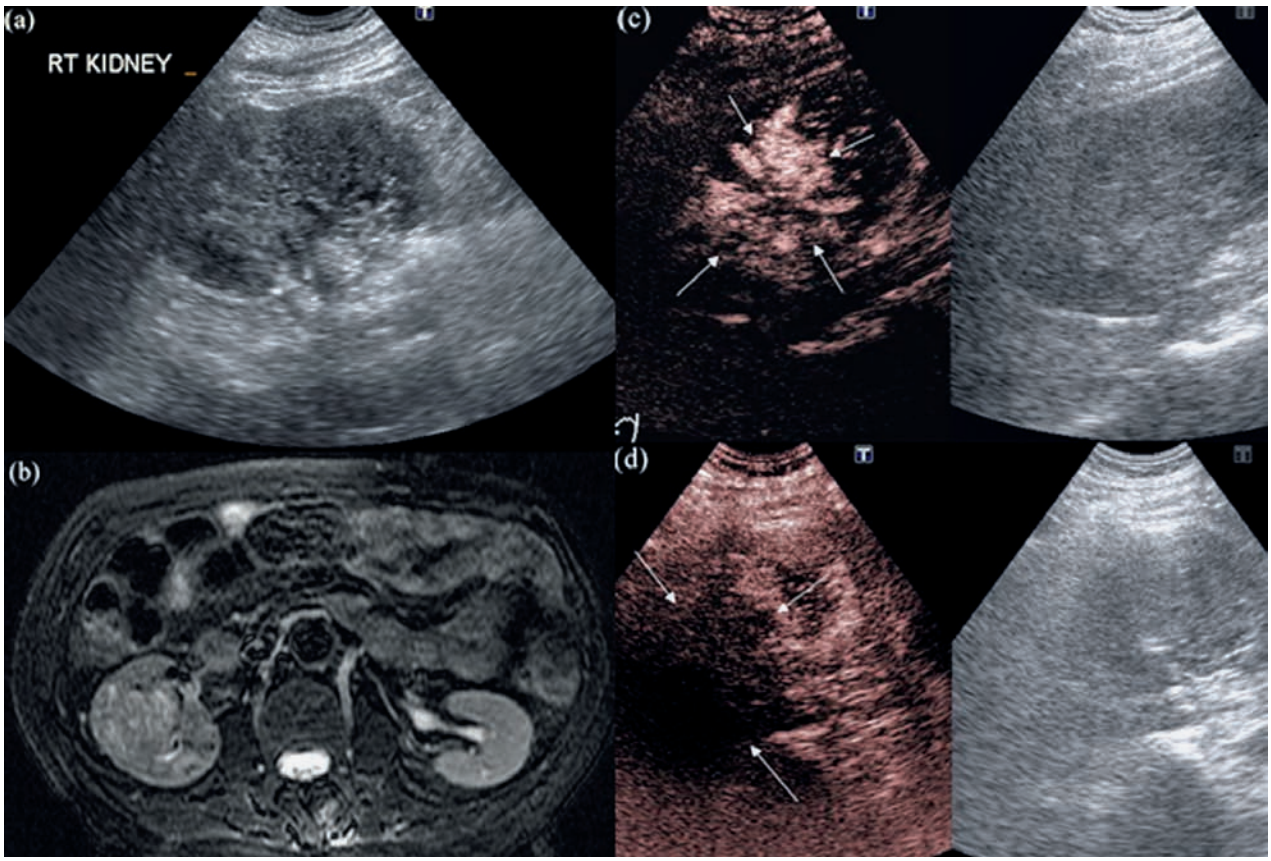

Fig 12. Renal cell carcinoma: a) Grey scale ultrasound image shows a hyperechoic mass at the upper pole of right kidney; b) T2 fat saturated axial MRI shows a slightly hyperintense mass in the right kidney. MRI gadolinium contrast agent was not given due to renal failure; c) Early phase CEUS image showing early contrast enhancement of the right renal mass (arrows); d) Medullary phase CEUS image showing early contrast washout in the right renal mass consistent with renal cell carcinoma (arrows).

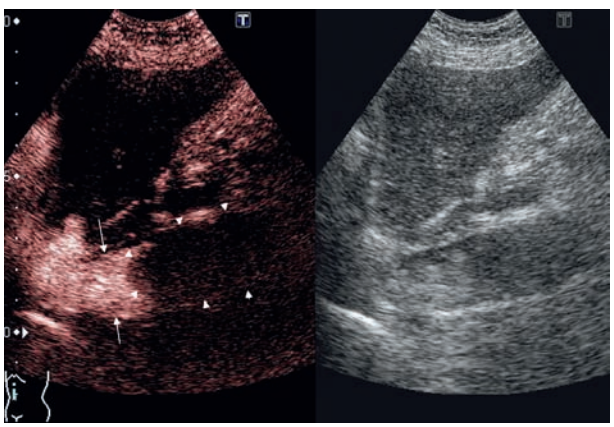

Fig 13. CEUS longitudinal image of inferior vena cave (arrows) in a patient with renal cell carcinoma show a non-enhancing hypoechoic mass (arrowheads) consistent with bland inferior vena cava thrombus rather than tumour thrombus.

Normal variants and pitfalls

A prominent column of Bertin (fig 14) or pyramid (fig 15) can mimic a mass on grey scale ultrasonography. On CEUS these pseudo-lesions exactly follow the normal enhancement pattern of the renal cortex or the pyramid and can thus be differentiated from a true renal mass lesion [9].

The wall between two simple cysts can be confused with an apparently enhancing septa (fig 16). This can cause higher Bosniak classification of a cyst and is a potential pitfall.

Use of ultrasound contrast agent improves the visualisation of entire renal vascularity and has shown to increase the number of diagnostic renal arterial Doppler studies [10]. We came across a patient with accessory renal artery that was difficult to appreciate on Doppler examination (fig 17).

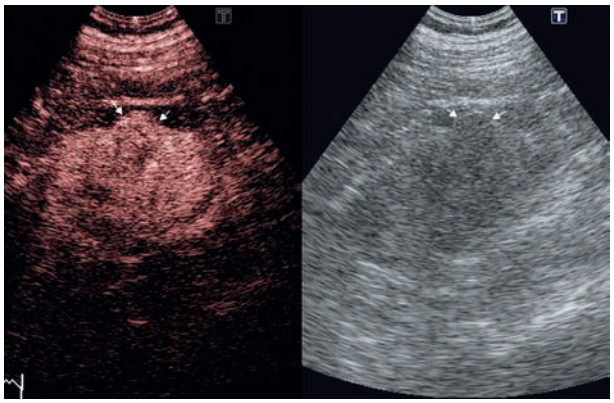

Fig 14. Prominent column of Bertin. CEUS image; apparent lesion at the right lower pole with cortical bulge (arrows) remained isoechoic with rest of the cortex in all phases of CEUS.

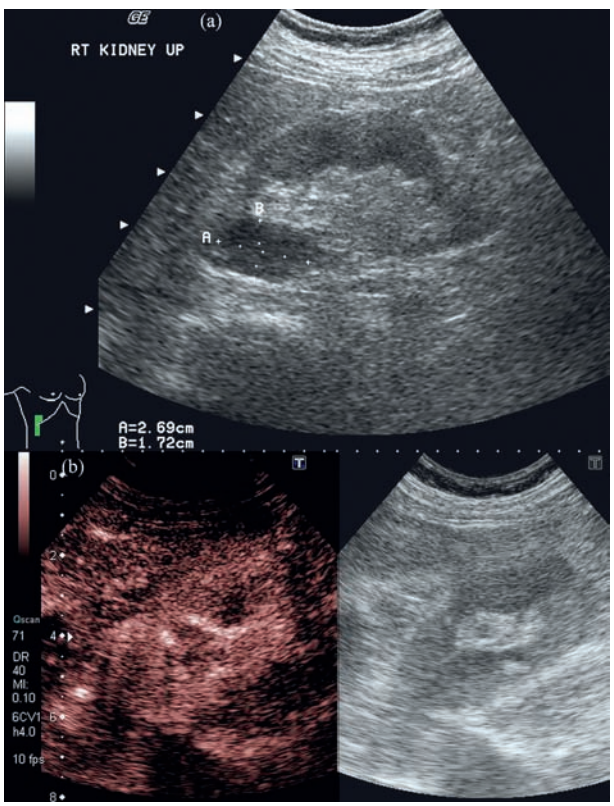

Fig 15. Prominent renal pyramid: a) Grey scale ultrasound demonstrated a hypoechoic lesion in the right upper pole (measured); b) CEUS showed this lesion to be isoechoic with rest of the pyramids in all phases of CEUS.

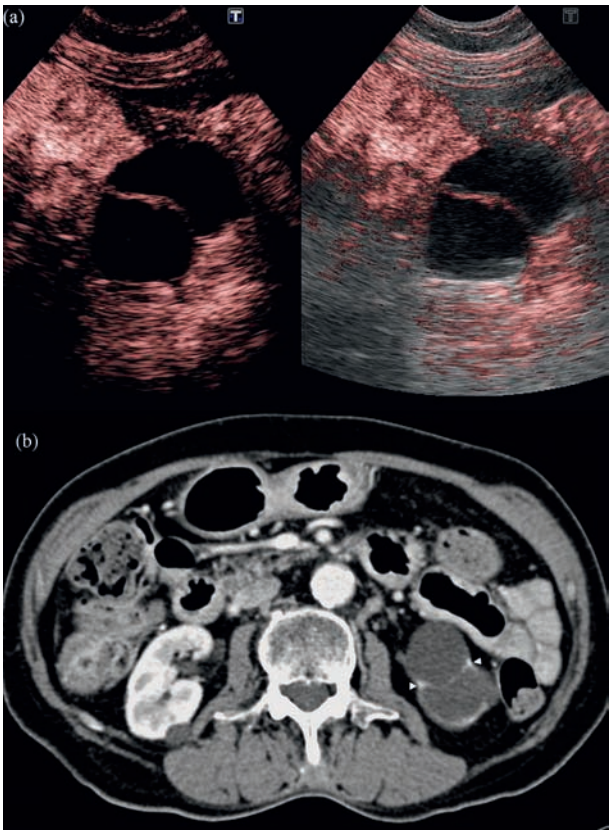

Fig 16. a) CEUS shows a septated left renal cyst with apparent enhancement of a septa; b) However, contrast enhanced CT scan demonstrates a 'claw' of renal parenchyma (arrowheads) suggesting that this lesion is made up of two simple cysts rather than a single septated cyst. This is a potential pitfall for higher Bosniak classification.

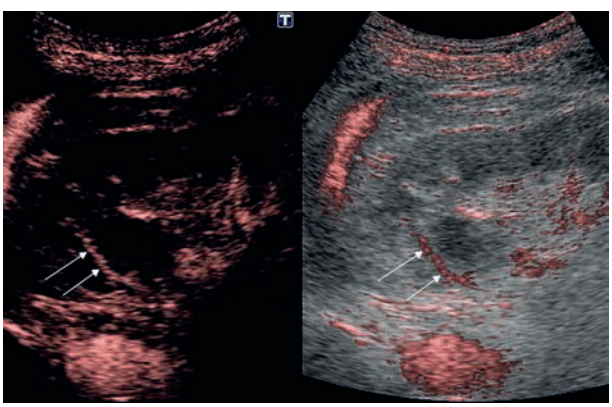

Fig 17. Early CEUS image 10 sec after intravenous injection of ultrasound contrast agent shows an accessory renal artery at the upper pole (arrows).

References

1. Jakobsen JA, Oyen R, Thomsen HS, Morcos SK; Members of Contrast Media Safety Committee of European Society of Urogenital Radiology (ESUR). Safety of ultrasound contrast agents. Eur Radiol 2005; 15: 941-945.
2. Reis M, Faria V, Lindoro J, Adolfo A. The small cystic and noncystic noninflammatory renal nodules: a postmortem study. J Urol 1988; 140: 721-724.
3. Isreal GM, Bosniak MA. How I do it: evaluating renal masses. Radiology 2005; 236: 441-450.
4. Ascenti G, Mazziotti S, Zimbaro G, et al. Complex cystic renal masses: characterization with contrast-enhanced US. Radiology 2007; 243: 158-165.
5. Dyer R, DiSantis DJ, McClennan BL. Simplified imaging approach for evaluation of the solid renal mass in adults. Radiology 2008; 247: 331-343.
6. Xu ZF, Xu HX, Xie XY, Liu GJ, Zheng YL, Lu MD. Renal cell carcinoma and renal angiomyolipoma: differential diagnosis with real-time contrast-enhanced ultrasonography. J Ultrasound Med 2010; 29: 709-717.
7. Dong XQ, Shen Y, Xu LW, Xu CM, Bi W, Wang XM. Contrast-enhanced ultrasound for detection and diagnosis of renal clear cell carcinoma. Chin Med J 2009; 122: 1179-1183.
8. Ascenti G, Gaeta M, Magno C, et al. Contrast-enhanced second-harmonic sonography in the detection of pseudocapsule in renal cell carcinoma. AJR Am J Roentgenol 2004; 182: 1525-1530.
9. Mazziotti S, Zimbaro F, Pandilfo A, Racchiusa S, Settineri N, Ascenti G. Usefulness of contrast-enhanced ultrasonography in diagnosis of renal pseudotumors. Abdom Imaging 2010; 35: 241-245.
10. Claudon M, Plouin PF, Baxter GM, Rohban T, Devos DM. Renal arteries in patients at risk of renal arterial stenosis: multicenter evaluation of the echo-enhancer SH U 508A at color and spectral Doppler US. Levovist Renal Artery Stenosis Study Group.Radiology 2000; 214: 739-746.