

Real-time sonoelastography in the diagnosis of prostate cancer

Călin R. Giurgiu¹, Cristian Manea¹, Nicolae Crișan¹, Cătălina Bungărdean², Ioan Coman³, Sorin M. Duda⁴

¹ Urology Department, Clinical Municipal Hospital, Cluj-Napoca, Romania

² Pathology Department, Clinical Municipal Hospital, Cluj-Napoca, Romania

³ Urology Desk, "Iuliu Hațieganu" University of Medicine and Pharmacy, Cluj-Napoca, Romania

⁴ Radiology Desk, "Iuliu Hațieganu" University of Medicine and Pharmacy, Cluj-Napoca, Romania

Abstract

Aims: Sonoelastography (SEG) is a noninvasive ultrasound (US) method able to differentiate tissues according to their stiffness. Our objective was to establish whether transrectal (TR) SEG may improve prostate cancer detection, alone or associated with other US methods. **Patients and methods:** We analyzed the data of 65 patients, mean age 68 years (49 - 81 years), examined March 2009-September 2010. The patients had at least one of the following malignancy suspicion criteria: PSA > 4 ng/ml (minimum 2 determinations), nodule(s) at digital rectal examination (DRE +) or previous gray scale TRUS positive appearance. All patients underwent TRUS, Doppler-US and SEG in the same session, followed by systematic prostate biopsies (6-12 cores). Histopathology and imaging findings were correlated. **Results:** Twenty-eight out of 65 patients (43%) were diagnosed with prostate cancer. Overall, SEG had a sensitivity of 67.85%, specificity 62.16%, positive predictive value 57.57% and negative predictive value 71.85%. However, SEG diagnostic reliability appeared to be higher for subgroups of patients having PSA >10 ng/ml, lower number of fragments collected by PBP (6 vs. 10-12 cores) and age > 70 years. **Conclusion:** SEG appears to be useful in the diagnosis of prostate cancer as it may increase the diagnosis accuracy in specific target groups.

Keywords: ultrasonography, sonoelastography, prostate cancer

Rezumat

Obiective: Elastografia (SEG) este o metodă neinvazivă ultrasonografică (US) capabilă să diferențieze țesuturile în funcție de consistența lor. Scopul cercetării este acela de a stabili dacă SEG transrectală (TR) poate ameliora depistarea cancerului prostatic, singură sau în asociere cu alte metode ultrasonografice. **Pacienți și metodă:** Au fost analizate datele a 65 pacienți cu vârsta medie 68 ani (49-81 ani), examinați în perioada martie 2009- septembrie 2010. Pacienții au prezentat cel puțin unul din următoarele criterii de suspiciune pentru malignitate: PSA > 4ng/ml (minim 2 determinări), examen digital rectal pozitiv sau modificări evocatoare la examinarea TRUS. Tuturor pacienților li s-a efectuat examinare ultrasonografică transrectală (în scară gri, Doppler-color și elastografie) în aceeași ședință urmată, ulterior, de puncție biopsie prostatică sistematică. Rezultatele examinării histopatologice au fost corelate cu achizițiile imagistice. **Rezultate:** 28 de pacienți din 65 (43%) au fost diagnosticați cu cancer prostatic. Global, SEG a avut sensibilitate 67,85%, specificitate 62,16%, valoare predictivă pozitivă (VPP) 57,57% și valoare predictivă negativă (VPN) de 71,85%. Cu toate acestea, valoarea diagnostică a SEG a fost mai mare pentru subgrupele de pacienți care au avut PSA >10 ng/ml, număr mai mic de fragmente la PBP (6 vs. 10-12 fragmente) și vârsta > 70 ani. **Concluzii:** Elastografia pare a fi utilă în diagnosticul cancerului prostatic deoarece poate crește acuratețea diagnostică la anumite grupuri țintă specifice.

Cuvinte cheie: ultrasonografie, elastografie, cancer prostatic.

Introduction

Sonoelastography (SEG) is a noninvasive ultrasound (US) method able to differentiate between tissues according to their stiffness [1]. Unlike gray-scale US, which assesses structures based on differences in acoustic impedance, SEG allows an "in depth palpation" of structures, visually defining them according to their relative hardness [2].

Received 10.12.2011 Accepted 11.01.2011

Med Ultrason

2011, Vol. 13, No 1, 5-9

Address for correspondence: Călin Giurgiu MD
4/4, Splaiul Independenței str,
400376, Cluj-Napoca, România,
Phone:+40752128026
Email: calingrcz@yahoo.com

The clinical utility of SEG has been extensively investigated, in recent years, for diagnosing breast lumps, thyroid nodules, prostate cancer but also musculoskeletal disease, pancreatic lesions, atherosclerosis and venous thrombosis [3-6]. The place of transrectal (TR) SEG in urological pathology and especially in prostate lesions is still controversial [7,8].

The goal of our study was to assess whether SEG may improve prostate cancer detection, alone or in association with other US methods (TRUS, Doppler).

Patients and Methods

Between March 2009 and September 2010 we examined 197 patients presenting with at least one of the following malignancy suspicion criteria: PSA > 4 ng/ml (at least two samplings), palpable nodule(s) at digital rectal examination (DRE +) or hypoechoic nodules in the outer gland on a previous transrectal gray-scale ultrasound (TRUS) examination. The study was approved by the hospital ethics committee and informed consent was obtained from the patients.

The equipment used was Hitachi Medical EUB 8500 ultrasound scanner with a 5–9 MHz broadband transrectal end fire microconvex probe.

All the patients underwent TRUS (gray scale, Doppler and SEG) in the same session. Gray scale images were assessed for: prostate size and volume; zonal morphology; presence of intraprostatic nodules; location and size of the nodules; ecogenicity of the nodules; other intraprostatic anatomic changes (calcification, cysts); state of the prostate capsule; size and symmetry of seminal vesicles. When assessing the power/color Doppler images, the following criteria were used: symmetry of vascularisation; focal area of hypervascularisation; distorted vessels; relation of abnormal vascularisation with nodules. The assessment criteria for SEG were: symmetry of stiffness; focal area of hardness, asymmetric; persistence of stiffness with probe tilting (fig 1, fig 2).

Malignancy was suspected when encountering the following criteria: on gray-scale US - hypoechoic nodule in the periphery gland +/- capsular and /or vesicular involvement; on power/color Doppler US - asymmetrical / focal increased vascularisation ; on SEG - stiff nodule > 5 mm diameter, persistent aspect after probe tilting (fig 1, fig 2).

Systematic TRUS guided prostate biopsy (6-12 cores) under local or general anesthesia was performed in every patient, within no more than 2 weeks after imaging assessment. The number of biopsy cores in each patient was imposed by the prostate size, local and general biopsy conditions. We did not use SEG for biopsy guidance.

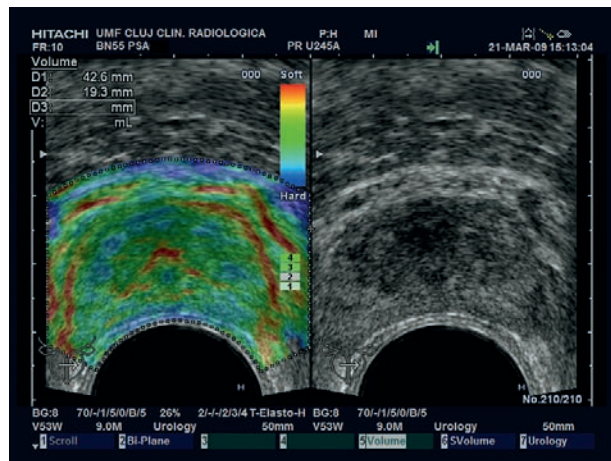


Fig 1. Normal prostate (SEG / TRUS)

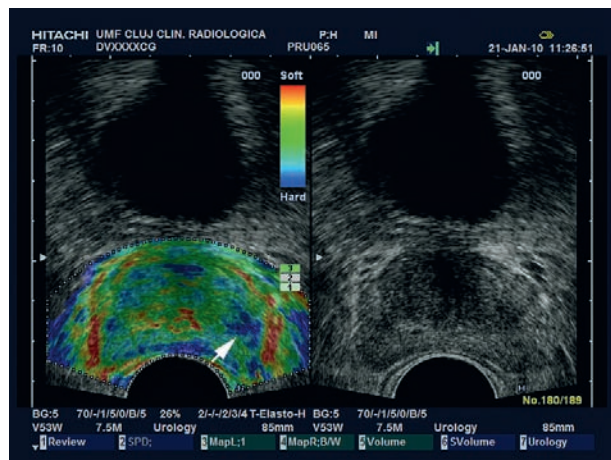


Fig 2. Prostate cancer (SEG / TRUS). The hard, malignant nodule in pointed by arrow.

Histopathology findings, considered as a reference standard, were correlated with the imaging appearance.

Out of the 197 patients enrolled, only 65 complied with the methodology, with the complete dataset acquired within the specified timeframe. The other 132 patients could not be included due to incomplete or delayed data. Within the patient group, we compared subgroups of patients in relation with the PSA value (cut off 10ng/ml), age (cut off 70 years), prostate volume (cut off 40 g) and number of biopsies (6 vs. 10-12). The results are described in statistical indices (sensitivity - SE, specificity - SP, positive predictive value - PPV, and negative predictive value - NPV). For statistical analysis Fisher's and Chi-square tests were used with the SPSS v 13.0 software, with the value $p < 0.05$ considered as significant.

Results

The mean age of the patients was 68 years (min 49, max 81). The PSA values ranged from 2.5 to 20.65 ng/ml. Prostate cancer was present in 28 patients (43%).

The general sensitivity of SEG was 67.85% (fig 3), similar to that of TRUS and higher than Doppler Ultrasound (60.71%). The general specificity of SEG (fig 4) was higher than that of the other ultrasound methods (SEG-62.16% vs. TRUS-54.35% or Doppler US –

40.54%). The PPV of SEG, defined as percent of patients with prostate cancer with relevant elastographic images, was 57.57 %, higher than the other methods (fig 5). The NPV of SEG, defined as percent of patients without cancer from those without a relevant elastographic images, was 71.85%, higher than all other methods used in the study (TRUS: 67.85%, Doppler: 57.69%) (fig 6).

The analysis of differences between subgroups according to PSA, age, prostate volume and number of fragments at prostate biopsy are presented in Table I.

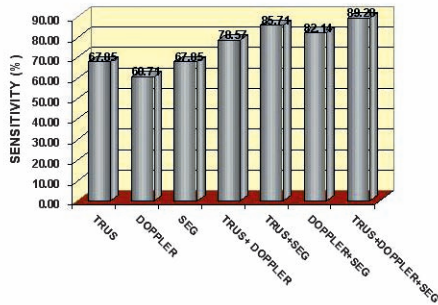


Fig 3. Overall sensitivity of US methods, alone or mutually associated, for the diagnosis of prostate cancer.

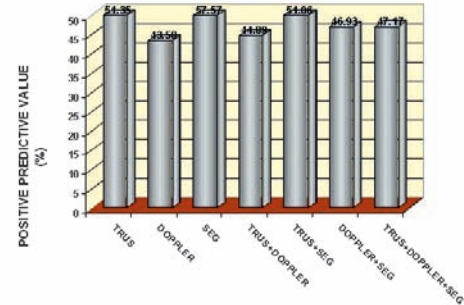


Fig 5. Overall positive predictive value of US methods, alone or mutually associated, for the diagnosis of prostate cancer.

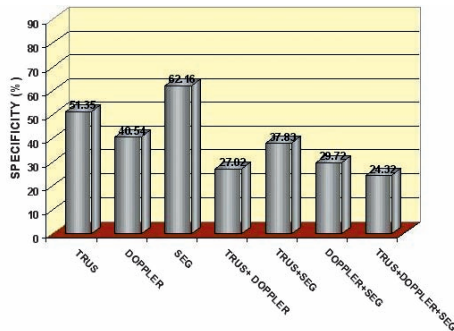


Fig 4. Overall specificity of US methods, alone or mutually associated, for the diagnosis of prostate cancer.

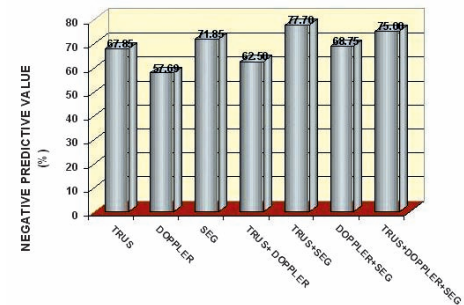


Fig 6. Overall negative predictive value of US methods, alone or mutually associated, for the diagnosis of prostate cancer

Table I. Statistical correlation (p) between different ultrasound methods and the diagnosis of cancer, depending on various parameters (chi-square with Fisher’s test). All results were plotted against pathology obtained at prostate biopsy.

Subgroup \ Method	TRUS	TRUS + SEG	TRUS + Doppler	SEG	SEG + Doppler	Doppler	TRUS + SEG + Doppler
Age >70 years	0.062	0.008	0.043	0.007	0.134	0.305	0.022
Age <70 years	0.582	0.513	0.374	0.380	0.740	0.554	0.969
Prostate volume > 40 cc	0.256	0.183	0.372	0.079	0.669	0.878	0.244
Prostate volume < 40 cc	0.550	0.110	0.494	0.068	0.306	0.840	0.761
PSA > 10 ng/ml	0.075	0.028	0.561	0.018	0.456	0.275	0.260
PSA < 10 ng/ml	0.880	0.565	0.685	0.438	0.467	0.321	0.611
Core biopsy 6 frag.	0.076	0.013	0.364	0.001	0.270	0.914	0.101
Core biopsy 10-12 frag.	0.883	0.778	0.711	0.883	0.773	0.883	0.831
Overall	0.121	0.036	0.624	0.017	0.271	0.919	0.161

TRUS = gray-scale transrectal ultrasound; SEG = real-time sonoelastography; PSA = prostate specific antigen

A cut-off value of 10 ng/ml was set for PSA. There were 38 patients below this value (11 cancers at pathological examination). Of the 27 patients with PSA values above the cut-off limit, 17 had cancer. There were significant differences between the subgroups. In the PSA > 10 ng/ml subgroup, SEG sensitivity was higher than SEG general sensitivity (76.47 % vs. 67.85%). Also, PPV of SEG was higher in this subgroup (84.25 vs. 57.57% in the general patient group).

For age-dependent analysis, a cut-off value set at 70 years revealed significant differences between subgroups. Of the 42 patients below 70 years of age, 16 had cancer. In the above 70 group, 12 of the 23 patients had cancer. In the > 70 years subgroup the sensitivity of SEG was 83.3 %, significantly higher than the sensitivity of the method for the below 70 years group (56.25%). A similar variation was noted for PPV (76.92% in subgroup > 70 years vs. 45% below 70 years). Furthermore, if SEG was associated with TRUS, NPV was 100% in the subgroup > 70 years ($p=0,008$).

For volume related analysis, a cut-off value was set at 40 cc, as determined by TRUS. SE, SP and NPV were higher in the subgroup > 40 cc vs. subgroup < 40 cc, but the difference was not statistically significant. However, when PPV was concerned, the value almost doubled (80%) in subgroup < 40 cc vs. 47.1% for subgroup > 40 cc.

In 38 patients, 6 core biopsy was performed. In this group, there were 18 cancers according to pathological examination. Of the 27 patients where 10 – 12 core biopsy was performed, 10 had cancer. In the subgroup with 6 core biopsies, the PPV of SEG was higher than in the subgroup with 10-12 fragments (75% vs. 33%). Accordingly, SE was also higher in the 6 core group (77.7%) compared to the 10-12 core group (50%). ROC analysis was not performed, due to the reduced number of patients in the analyzed subgroups.

Discussion

The elastographic image of the normal prostate (see figure 1) is that of a homogeneous medium stiffness tissue. At times, one may encounter a hard peripheral zone (next to the prostate capsule) and a hard zone at the level of the “veru montanum” region [8].

Malignant nodules are of hard consistency and they appear as dark areas on gray scale and hard (blue) asymmetric areas on SEG color image. Most of the times, malignancy is clearly differentiated from the surrounding tissue that exhibits lower consistency, with green shades on SEG color image (see figure 2).

In terms of overall sensitivity, our results are similar

to those of an extensive study performed in Japan with over 311 patients and published recently [9].

Subgroup tailored data revealed interesting observations. It seems that in subgroup with PSA < 10 ng/ml, none of the US diagnostic methods (alone or in association) correlated with prostate cancer ($p>0.05$). Therefore, our study indicates that no ultrasonographic method is able to improve prostate cancer detection in patients with PSA < 10 ng/ml. This might be due to low grade/good differentiation of low PSA tumors. On the other hand, our data indicate that in the subgroup with PSA > 10 ng/ml only SEG results are correlated with prostate cancer, either alone or in association with TRUS.

Aggregate data in our study suggest that a person over 70 years with moderate elevated PSA levels and without suggestive TRUS or SEG images has very little chance of harboring prostate cancer. This raises the question of the necessity of a prostate biopsy in these patients. A possible explanation may reside in the fact that “younger” patients tend to develop high grade malignancy with poor local intra-prostatic delineation of lesions, leading to worse identification by ultrasonographic methods. On the other hand, in the “older” subgroup (> 70 years) predominant low grade prostate malignancies are developing with macroscopic, even massive, local lesions, better identified by imaging. One other factor to be taken into account is that, possibly, false results (both positive and negative) are more frequently encountered in the < 70 years group. From this point of view, our data need to be expanded as the statistical correlation is insignificant.

A possible explanation for limitations is that in the group with large prostates there is a large number of discordant elastographic images (associated prostatitis lesions, benign prostate hypertrophy hard nodules, attenuation effect or distance effect etc).

According to the results of our study, the specificity of SEG appears to be superior to that of other ultrasound techniques.

The goal of prostate imaging is to detect intra-prostatic cancerous nodules with fewer prostate biopsy punctures, decreased morbidity (sepsis, hemorrhage) and reduced costs [10]. Controversial results persist, even with studies published earlier by our group [11]. One of the possible explanations is related to the diagnostic criteria used in this study for SEG suspicion of malignancy. We complied with the criteria originally described by König et al [12]. Therefore, only tumors with a diameter above 5 mm were taken into account. However, it is probable that applying the newer scores proposed by Pallwein et al [13] or Kamoi et al [14] may lead to the detection of smaller tumors and the improvement of SEG sensitivity. Another explanation is that the “golden standard” used

(TRUS prostate biopsy), in itself, has known limitations and detects at most 80% of all cancers found at autopsy [15]. In this respect, the partial results of our study offer a tailored positive perspective.

Conclusions

SEG is a promising diagnostic method, alone or in association with other US methods. TRUS (gray scale or Doppler), is not correlated with the diagnosis of prostate cancer in all subgroups of patients studied. SEG diagnostic reliability seems higher for patients having PSA > 10 ng/ml and a lower number of fragments collected by prostate biopsy puncture and age > 70 years. Although a promising method, the role of SEG as a diagnostic tool in the detection of prostate cancer needs to be assessed and confirmed by further studies.

Conflict of interest: absence of conflict of interest

References

- Ophir J, Cespedes I, Ponnekanti H, Yazdi Y, Li X. Elastography: a quantitative method for imaging the elasticity of biological tissues. *Ultrason Imaging* 1991; 13: 111-134.
- Dudea SM, Dumitriu D, Botar-Jid C. Principii fizice ale elastografiei ultrasonore. *Rev Rom Ultrason* 2007; 9: 45-52.
- Ginat DT, Destounis SV, Barr RG, Castaneda B, Strang JG, Rubens DJ. US Elastography of Breast and Prostate Lesions. *Radiographics* 2009; 29: 2007 - 2016
- Garra BS. Imaging and estimation of tissue elasticity by ultrasound. *Ultrasound Q* 2007; 23: 255- 268.
- Dumitriu D, Dudea SM, Botar-Jid C, Ciurea A, Chiorean A. Aplicatii clinice ale elastografiei ultrasonore. *Rev Rom Ultrason* 2007; 9: 117- 126.
- Pallwein L, Mitterberger M, Pelzer A, et al. Ultrasound of prostate cancer: recent advances. *Eur Radiol* 2008; 18: 707-715.
- Eggert T, Khaled W, Wenske S, Ermert H, Noldus J. Impact of elastography in clinical diagnosis of prostate cancer. A comparison of cancer detection between B-mode sonography and elastography-guided 10-core biopsies. *Urologe A* 2008; 47: 1212-1217.
- Salomon G, Graefen M, Heinzer H, et al. The value of real-time elastography in the diagnosis of prostate cancer. *Urologe A* 2009; 48: 628- 636.
- Miyagawa T, Tsutsumi M, Matsumura T, et al. Real-time elastography for the diagnosis of prostate cancer: evaluation of elastographic moving images. *Jpn J Clin Oncol* 2009; 39: 394-398.
- Nelson ED, Slotoroff CB, Gomella LG, Halpern EJ. Targeted biopsy of the prostate: the impact of color Doppler imaging and elastography on prostate cancer detection and Gleason score. *Urology* 2007; 70: 1136- 1140.
- Giurgiu CR, Dudea SM, Coman I. Elastography in the early detection of prostate cancer. *J Radiother Med Oncol* 2010; 16: 89 – 93.
- Konig K, Scheipers U, Pesavento A, Lorenz A, Ermert H, Senge T. Initial experiences with real-time elastography guided biopsies of the prostate. *J Urol* 2005; 174: 115–117.
- Pallwein L, Aigner F, Pinggera G, Mitterberger M, Frauscher F, Bartsch G. Is real-time elastography targeted biopsy able to enhance prostate cancer detection? Value of an elasticity-scoring system, American Urological Association Annual Meeting, 2008, May 17–22, Orlando, USA.
- Kamoi K, Okihara K, Ochiai A, et al. The utility of transrectal real-time elastography in the diagnosis of prostate cancer. *Ultrasound Med Biol* 2008; 34: 1025-1032.
- Haas GP, Delongchamps NB, Jones RF, et al. Needle biopsies on autopsy prostates: sensitivity of cancer detection based on true prevalence. *J Natl Cancer Inst.* 2007; 99: 1484-1489.