

## The role of ultrasonography in Albendazole treatment of hydatid liver cyst monitoring in children – three case reports

Horațiu Gocan, Adrian Surd, Ioan Dobrescu, Emilia Pop

Emergency Hospital for Children, Department of Pediatric Surgery, Cluj-Napoca

### Abstract

Hydatid liver cyst represents a zoonosis caused by *Echinococcus granulosus*. The condition has been known for over 2000 years, with endemic spreading areas in sheep-raising regions of the world, including Africa, the Mediterranean region, Middle East, Asia, Australia, South America and New Zealand. **Overview:** This paper describes various aspects of Albendazole chemotherapy used in patients with a clear diagnosis of a hydatid hepatic cyst. The diagnosis is relatively easy to formulate, and the imagistic evaluation is used for differential diagnosis and for follow-up in treated patients. Ultrasound images presented in this article show the evolution of hydatid hepatic cyst under Albendazole treatment. **In conclusion,** hydatid hepatic cyst is a condition in which long therapy with Albendazole has good results in patient with primary disease but also in cases of relapse, and is an important alternative to surgery.

**Key words:** Albendazole, hydatid liver cyst, ultrasonography

### Rezumat

Chistul hidatic hepatic reprezintă o zoonoză a cărei agent determinant este reprezentat de *Echinococcus granulosus*. Afecțiunea este cunoscută de mai bine de 2000 de ani, având o răspândire endemică în ariile de creștere a oilor în regiunile din Africa, regiunea Mediteraneană, Orientul mijlociu, Asia, Australia, America de Sud și Noua Zeelandă. **Prezentare generală:** Articolul de față propune evaluarea diverselor aspecte ale chimioterapiei cu Albendazol, utilizată la pacienții cu diagnostic cert de chist hidatic hepatic. Diagnosticul este relativ ușor de formulat, evaluarea imagistică fiind utilizată atât pentru un diagnostic diferențial dar și în urmărirea pacienților la care s-a început terapia medicamentoasă. Imaginile ecografice prezentate surprind evoluția din punct de vedere ecografic a unor pacienți diagnosticați cu chist hidatic hepatic sau care au prezentat recăderi după sistarea chimioterapiei cu Albendazol. **În concluzie,** chistul hidatic hepatic rămâne o afecțiune în care terapia îndelungată cu Albendazol aduce rezultate benefice atât pacientului cu boală primară cât și în cazul unor recăderi, rămânând o alternativă la intervenția chirurgicală.

**Cuvinte cheie:** Albendazol, chist hidatic hepatic, ecografie

### Introduction

The hydatid liver cysts represents a pathology that raises medical and surgical problems regarding the therapeutical plan. The clinical picture ranges from an

asymptomatic cases, to hepatomegaly and complications such as rupture of the cyst and all the problems that can emerge from this complication. Mostly the diagnosis is made using imaging investigations such as ultrasound or computer tomography. The therapy is not always a surgical one. By using a chemotherapeutic agent, Albendazole or Mebendazole, it is possible to obtain total remission of the hydatid cyst and to avoid complications caused by surgery [1].

### Cases presentation

We present three cases hospitalized in the Department of Pediatric Surgery, Cluj Napoca, diagnosed with hy-

Received 10.07.2010 Accepted 4.10.2010

Med Ultrason

2010, Vol. 12, No 4, 340-344

Address for correspondence:

Dr. Gocan Horatiu  
University of Medicine and Pharmacy  
„Iuliu Hațieganu” – Department of  
Pediatric Surgery and Orthopedy  
Cluj-Napoca  
68 Motilor str, Cluj-Napoca, Romania  
E-mail: horatiugocan@yahoo.com

datid liver cyst. In all three cases the patients followed chemotherapy with Albendazole and ultrasonography was used for diagnosis and monitoring.

**Case no. 1**

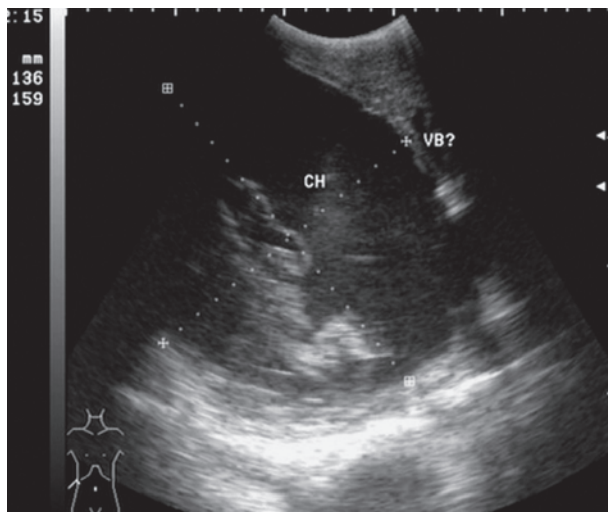
Patient B.C, male, 16 years old, from a rural area was hospitalized in the Department of Pediatric Surgery from Cluj Napoca in October 2005 for the presence of a liver cystic formation.

Physical examination at admission revealed liver about 2.5 cm below the rib, without other changes in systems. Laboratory investigations revealed a high value of eosinophils (32 %) and the Echinococcus antibodies type G immunoglobulin were positive.

The liver ultrasound revealed three cystic images with an aspect suggestive for hydatid cyst.

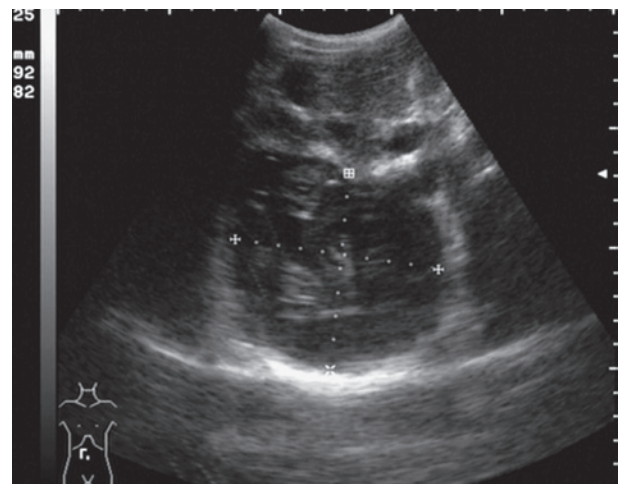
Considering the clinical and imaging picture, we decided to initiate the therapy with Albendazole, 15 mg/kg body weight/day. This therapy was administered in two divided doses each day for 28 days, followed by a break of 15 days. Four cycles of therapy were conducted, during which we regularly monitored the liver enzyme without complications such as liver failure.

The aspect of one of the hydatid cysts (size 136/159 cm) before the therapy with Albendazole is presented in fig 1.



**Fig 1.** Liver ultrasound evidenced in Case 1 a large hydatid cyst with inhomogenous aspect, hypochoic content, and echogenic strips inside (membrane). The cyst presents acoustic enhancement.

Ultrasound evaluation one year after initiation of the chemotherapy with Albendazole, in regular courses, revealed an almost 50 % reduction in size in all three liver cysts. Given this reduction in size it was decided

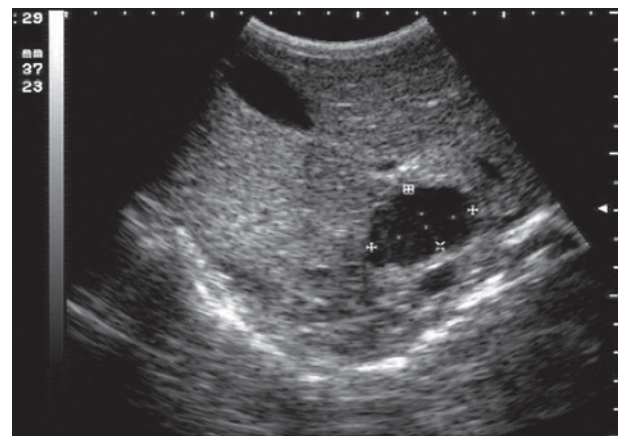


**Fig 2.** Liver cyst in Case 1 decreased in size after drug therapy.

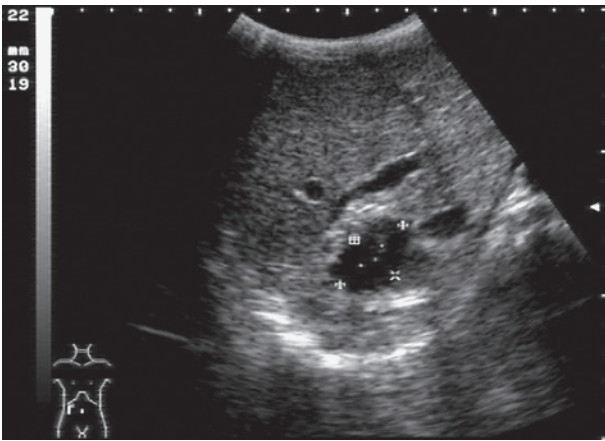
to continue the therapy with Albendazole, the same dose and in repeated cycles. A new decreased in cyst size was observed one year after (fig 2).

**Case no. 2**

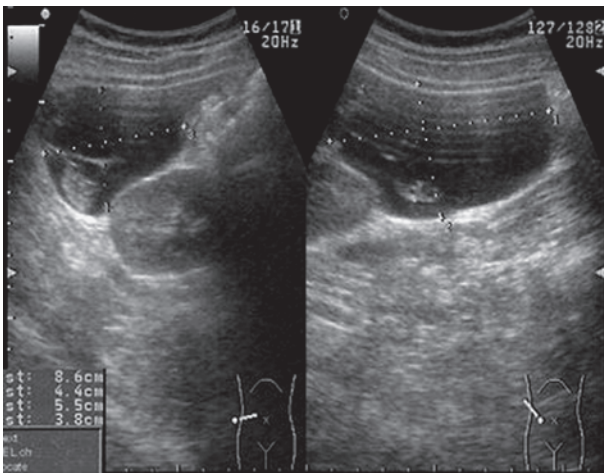
V.D, male, 7 years old, was evaluated in our clinic in August 2000 for abdominal pain. Following a routine examination, an abdominal ultrasound detected the presence of cystic lesions in the liver and the spleen. Further investigations led to the interpretation of the case as a hidatid cyst of the liver and spleen, with subsequent initiation of therapy with Albendazole. The patient followed repeated cycles for 28 days with Albendazole (15 mg/kg body weight/day) for one year, with periodical determination of the liver enzyme levels. Fig 3 presents the ultrasound appearance at the first evaluation.



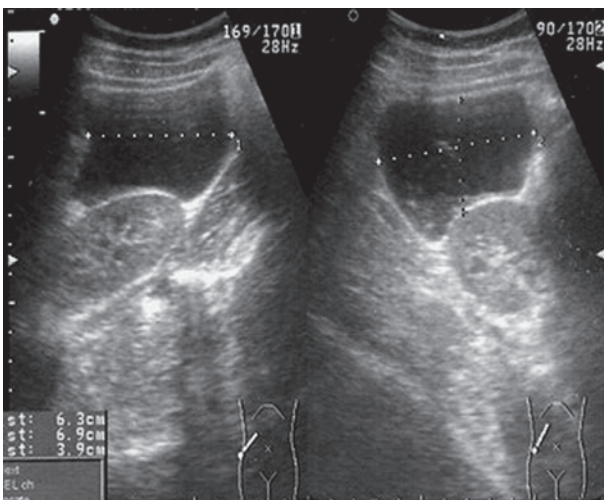
**Fig 3.** Liver ultrasound in Case 2 revealed a transsonic cyst (3.7/2.3 cm) with acoustic enhancement.



**Fig 4.** Albendazole treatment determined cyst reduction in Case 2 (size of 3/2 cm).



**Fig 5.** Liver ultrasound in Case 3 revealed a large cyst (8.5/4.5 cm) with thin wall and echoic content inside.



**Fig 6.** Albendazole treatment led to the reduction of the liver cyst presented in Figure 5 (7/4 cm).

Albendazole therapy favorably influenced the outcome of this patient. After one year of the cycles of Albendazole chemotherapy a reduction in the size of the liver cyst was observed (fig 4) and no other cyst in the liver and spleen was found. There were no complications regarding the liver function.

### Case no.3

A patient aged 16, female, V.M, from an urban area was transferred to our department from a territorial hospital unit where she had been hospitalized for a recurrent abdominal pain syndrome. Ultrasound revealed multiple liver cysts which resulted in raising the suspicion of hidatid liver cysts.

Physical examination was normal and laboratory investigations revealed a slight increase in the percentage of eosinophils and liver enzymes. The Echinococcus antibodies type G immunoglobulin were positive.

The ultrasound performed in our clinic described the presence of three liver cysts, located in the liver-segments III, IV and VI, ranged between 86/44 cm and 30/25 cm. The largest cyst ultrasonographic aspect is shown in fig.5.. The ultrasonographic aspect, in conjunction with laboratory findings allowed a reliable diagnosis of hidatid liver cysts.

A favorable decrease in size of all liver cysts (fig 6) eight months after a cyclic Albendazole therapy, 15 mg/kg body weight/day was observed. A slight increase in the liver enzymes level after drug therapy was revealed .

### Discussion

The term of "liver cyst" refers mostly to a nonparasite solitary liver cyst. Often a simple liver cyst must be differentiated from other cystic liver lesions. This category includes also multiple cysts from polycystic liver disease, hydatid or other parasitic cyst, cystic tumors or abscesses. A differential diagnosis is usually based on clinical and imagistic findings.

There are three species of the *Echinococcus genus* that may determine in humans various forms of hydatid disease, the most common being *Echinococcus granulosus*. The most frequently affected organs in hydatid disease is the liver, followed by lung, brain and other organs. Most patients presents a palpable mass or pain in the upper right abdomen quadrant Another clinical aspect could be represented by jaundice or hepatomegaly. The most complex clinical aspect is given by a perforated hydatid cyst with subsequent disposal in the abdominal cavity leading to peritonitis and anaphylactic shock. Some hydatid cysts become infected and determine a liver abscess [2].

The diagnosis is based on laboratory investigations and on imaging findings. Ultrasonography should be the first option in a liver hydatid cyst diagnosis. Ultrasonography is able to detect liver masses with heterogeneous structure and calcifications. The most reliable imaging investigation of calcifications is computer tomography. This investigation allows at the same time a possible preoperative evaluation of the extension of the disease or the involvement of the neighboring vascular structures. Magnetic resonance imaging allows the depiction of a pathognomonic aspect of hydatid cysts, described as a „bunch of grapes” or a „honeycomb”.

Specific antibodies to *Echinococcus granulosus* are required to determine a complete diagnosis of hydatid cysts. After diagnosis the most important step is the therapy treatment. There are three ways of treating the hydatid cyst: chemotherapy, surgery and percutaneous drainage.

Surgical management of hepatic hydatid cyst involves radical and conservative interventions.

Percutaneous drainage has long been rejected in order to avoid the risk of cystic rupture into the abdominal cavity, which could lead to anaphylaxis and seeding of intraperitoneal structures. There are many situations in which percutaneous drainage is preceded and followed by administration of chemotherapy.

Chemotherapy with effective medication against *Echinococcus* species, used before and after a possible surgery intervention is widely used. The main therapy is with high doses of antiparasitic drugs such as Albendazole and Mebendazole. Among the factors that influence the outcome of the chemotherapy are chemotherapy drug type, the age of the cyst, the patient's age and the location and morphological characteristics of the cyst [1].

Albendazole is the first therapeutic choice in patients that are not able to undergo a surgical intervention or refuse surgery, in relapsed cases or if there are too many cysts. Chemotherapy is used also in asymptomatic patients.

Albendazole is metabolised in the liver to form albendazole sulfoxide, which is the active metabolite. This compound reaches various concentrations in blood, gall bladder, liver tissue, intracystic fluid and cyst walls and then passes through the hematoencephalic barrier. The maximum peak level after the administration of Albendazole is reached in four hours and the half-life in serum is about six to fifteen hours. After administration of Albendazole high serum levels are achieved, followed by the penetration into the cyst.

People weighing over 60 kg will receive 400 mg of Albendazole per day in two doses. Patients weighing under 60 kg will receive 15 mg/kgcorp/day in two doses,

with a maximum of 800 mg in 24 hours. Therapy is generally managed in one to six monthly cycles, separated by free intervals of 10-14 days.

The most feared secondary effects of therapy with Albendazole are considered to be hepatic and haematological toxicity. Patients receiving therapy with Albendazole must perform during therapy, every two weeks, blood counts and measurements of liver enzymes [3].

Most clinical studies that have followed the evolution of the disease after therapy with Albendazole or Mebendazole have shown that Albendazole is more active in vitro compared with Mebendazole, presents a gastrointestinal absorption and a much better bioavailability, but also more encouraging clinical results [4-9].

Franchi *et al* followed the response to therapy with Albendazole and Mebendazole in 448 patients diagnosed with hydatid liver cyst. In 74 % of cases they observed degenerative changes and an efficacy of Albendazole of 82 % compared with Mebendazole (56%). However, in 25 % of cases they observed cystic regeneration. The failure rate was the same in patients who received Albendazole or Mebendazole. Most relapses were observed in patients having daughter-cysts besides the mother-cyst; in most cases the observation was seen in patients with liver cysts compared to those with other localisation such as lung cysts. Of the cases included in the study, ¾ had relapsed in the first two years of the cessation of therapy and more than 90 % of relapses has been solved after another treatment with antiparasitic therapy [10].

A clinical study conducted by Teggi *et al* included 337 patients with different locations of a hydatid cyst. The aim of this study was to compare the response obtained after administration of Albendazole and Mebendazole. The outcome in patients treated with Albendazole was better compared with the outcome of patients treated with Mebendazole. Degenerative changes were observed in 80% of patients treated with Albendazole and in 50.6 % of patients receiving therapy with Mebendazole. The relapse was detected in 30% of patients and 95% had a good evolution after the resumption of drug therapy [1].

The Albendazole therapy was effective in all patients presented in this paper. There was a decrease in size in all liver cysts, no other hydatid cysts were found and there were no complications after drug therapy.

**In conclusion**, hydatid hepatic cyst remains a condition in which long therapy with Albendazole has good results in patients with primary disease and also in cases of relapse. Albendazole therapy represents a reliable alternative to surgery in children with hydatid liver disease.

**References**

1. Teggi A, Lastilla MG, de Rosa F. Therapy of human hydatid disease with mebendazole and albendazole. *Antimicrob Agents Chemother* 1993; 37: 1679-1684.
2. Smego RA Jr, Sebanego P. Treatment options for hepatic cystic echinococcosis. *Int J Infect Dis* 2005; 9: 69-76.
3. Smith AL, Rego LP, Williams R. Albendazole monitoring. *Am J Health Syst Pharm* 1997; 54: 319-320.
4. Senyuz OF, Yesildag E, Celayir S. Albendazole therapy in the treatment of hydatid liver disease. *Surg Today* 2001; 31: 487-491.
5. Nahmias J, Goldsmith R, Soibelman M, el-On J. Three- to 7-year follow-up after albendazole treatment of 68 patients with cystic echinococcosis (hydatid disease). *Ann Trop Med Parasitol* 1994; 88: 295-304.
6. Todorov T, Vutova K, Petkov D, Mechkov G, Kolev K. Albendazole treatment of human cystic echinococcosis. *Trans R Soc Trop Med Hyg* 1988; 82: 453-459.
7. Keshmiri M, Baharvahdat H, Fattahi SH, et al. Albendazole versus placebo in treatment of echinococcosis. *Trans R Soc Trop Med Hyg* 2001; 95: 190-194.
8. Saimot AG. Medical treatment of liver hydatidosis. *World J Surg* 2001; 25: 15-20.
9. Fenton-Lee D, Morris DL. The management of hydatid disease of the liver. Part 2. *Trop Doct* 1997; 27: 87-88.
10. Franchi C, Di Vico B, Teggi A. Long-term evaluation of patients with hydatidosis treated with benzimidazole carbamates. *Clin Infect Dis* 1999; 29: 304-309.