Review

Medical Ultrasonography
2010, Vol. 12, no. 2, 139-144

Femoral nerve blockade

Szilard Szucs[1], Didier Morau[2], Gabriella Iohom[3]

[1] MD, Research Fellow
[2] MD, Clinical Lecturer
[3] MD, PhD, Consultant Anaesthetist/Senior Lecturer, Department of Anaesthesia and Intensive Care Medicine, Cork University Hospital, Cork, Ireland

Abstract

Femoral nerve blockade is the most widely performed lower limb block. Methods of femoral nerve blockade are briefly reviewed with particular reference to ultrasound guidance.

Keywords: femoral nerve, anaesthetic block, ultrasonography

Rezumat

Blocajul anestezic al nervului femural este cel mai frecvent blocaj efectuat la nivelul membrului inferior. Sunt trecute în revistă metodele de blocaj anestezic ale nervului femural, cu referire în particular la ghidajul ecografic

Cuvinte cheie: nerv femural, bloc anestezic, ecografie

Introduction

Femoral nerve blockade is widely practiced by phisicians in a variety of circumstances, i.e. analgesia for femur fractures in pre-hospital medicine [1], in the accident and emergency departments and in the clinical setting of perioperative care [2]. Femoral nerve blockade is likely to be the most widely performed lower limb block.

Anatomy

The femoral nerve is a terminal branch of the lumbar plexus [3]. It arises from the ventral rami of the second, third and fourth lumbar nerves and it descends through the substance of the psoas major muscle, emerging from the muscle at the lower part of its lateral border. It runs in the gutter of the iliopsoas muscle under the fascia iliaca, it then passes behind the inguinal ligament and enters the femoral triangle. At this level the fascia along the internal aspect of the iliopsoas thickens to form the iliopectineal band that separates the femoral vessels from the nerve.

The femoral nerve divides into superficial and deep terminal branches in the femoral triangle [4]. The superficial branches include the lateral musculocutaneous nerve which innervates the sartorius muscle and the skin of the anterior thigh; and the medial musculocutaneous nerve which divides to innervate the pectineus muscle, the articular surface of the acetabulum, and skin of the medial thigh.

The deep branches comprise the saphenous nerve and the branches which innervate the quadriceps muscles - rectus femoris, vastus lateralis, vastus medialis and vastus intermedius muscles. The saphenous nerve is sensory only and supplies the skin of the medial leg as far as the medial malleolus. In the thigh it descends with the nerve to the vastus medialis muscle.

Applied anatomy

Dermatomal innervation

Femoral nerve blockade results in anaesthesia of the skin of the antero-medial thigh (femoral nerve), knee (femoral nerve) and the medial border of the leg (saphenous nerve).

Received 30.03.2010 Accepted 6.04.2010
Med Ultrason
2010, Vol. 12, No 2, 139-144
Address for correspondence: Szilard Szucs
Department of Anesthesia,
Cork University Hospital, Wilton,
Cork, Ireland.
Telephone: +353214922135
Fax: +353214546434
Email: szilard.szucs@yahoo.ie

Myotomal innervation

The main muscles innervated by the femoral nerve are the sartorius, quadriceps femoris (rectus femoris, vastus lateralis, intermedius and medialis), as well as the iliopsoas and pectineus muscles.

Osteotomal innervation

The femoral nerve innervates the anterior wall of the hip joint, the anterior aspect of the femur and the anteromedial walls of the knee joint.

Indications

Analgesia in the following scenarios

Fractured neck/shaft of femur

Hip joint (following total hip replacement)

Knee joint (following anterior cruciate ligament repair, total knee replacement)

Anaesthesia. Alone: skin graft from the anterior aspect of the thigh, muscle biopsy

In combination with a popliteal block (any procedure on the foot and lower leg), with high sciatic and obturator blocks (any procedure on the lower limb)

Targeted femoral nerve block

The femoral nerve is situated most superficially at the level of inguinal crease, although its relative depth may vary [3]. Femoral nerve blockade has been attempted blindly in the past, with a sharp needle, 1-1.5 cm laterally from the femoral pulse. Paraesthesia technique followed, based on eliciting paraesthesia in the femoral innervation area. Peripheral nerve stimulation techniques have the added benefit of targeting more precisely the nerve while minimizing potential nerve injury. The classical endpoint for injection in the case nerve stimulator guided femoral block is the 'dancing patella' sign, i.e. quadriceps contraction [2].

Fascia iliaca (iliacus) compartment block – an indirect femoral nerve block

Following an injection under the fascia iliaca in the inguinal region (iliacus or fascia iliaca block), anaesthetic solution is distributed to the femoral nerve (>90%), lateral femoral cutaneous nerve (>85%) and occasionally to the genito-femoral nerve.

The fascia iliaca block is very similar to the femoral nerve block in terms of extent of blockade, although the lateral femoral cutaneous nerve (sometimes called the lateral cutaneous nerve of the thigh) is blocked more consistently with this approach compared with a femoral block [3].

The fascia iliaca block was initially described in children and then extrapolated to adults. The main landmark for its performance is the inguinal ligament outlined by a line connecting the anterior superior iliac spine and the pubic tubercle. The needle insertion point is approximately one cm below of the junction between the outer on-third and inner two-thirds of this line. Block performance is based on the highly unrelible 'two pop' feel as a result of piercing the fascia lata and the fascia iliaca [5].

Sonoanatomy

The femoral nerve block is ideally suited for ultrasound guidance with a high frequency (>10 MHz) linear probe because of the relatively superficial position of the femoral nerve [6, 7]. Distal to the inguinal ligament, the femoral nerve lies lateral to the femoral artery, deep to the fascia iliaca, on the anterior aspect of the iliopsosas muscle (fig 1). The artery is easily located due to its pulsation and/or flow identified by doppler (fig 2, fig 3). The femoral nerve is often found within a triangular hyperechoic region, lateral to the femoral artery and superficial to the iliopsoas muscle. The femoral nerve may be quite thin and flat in this region as the nerve fans out into multiple branches. The nerve may also appear as a biconvex or oval hyperechoic structure.

From superficial to deep, the fascia lata is first encountered, then the fascia iliaca (hyperechoic line). Inguinal lymph nodes also appear hyperechoic and hence may be confused with the nerve in the short axis view. A nerve is a continuous structure that can be traced (by scanning proximally and distally) while a lymph node is not and can be seen only in a discrete location.

The ultimate aim is to deposit local anaesthetic solution adjacent to the femoral nerve in order to ensure a successful block. Similarly to other ultrasound guided blocks, an aggressive and a more conservative approach may be described. The first would typically aim to surround the femoral nerve with a pool of local anaesthetic (often referred to as the 'doughnut sign'), and would correspond to the classical femoral nerve block (fig 4). Ultrasound guidance, through a more precise injection has allowed for a reduction of the effective local anaesthetic dose. The conservative approach would correspond to the classical fascia iliaca block, i.e. injecting at a distance from the nerve under the fascia iliaca and observing the spread of local anaesthetic solution towards the femoral nerve. Due to contrast enhancement, following injection of the hypoechoic local anaesthetic, often the hyperechoic femoral nerve becomes more prominent (fig 5).

Ultrasound guidance may facilitate peripheral nerve blockade in many ways, including visualization of the

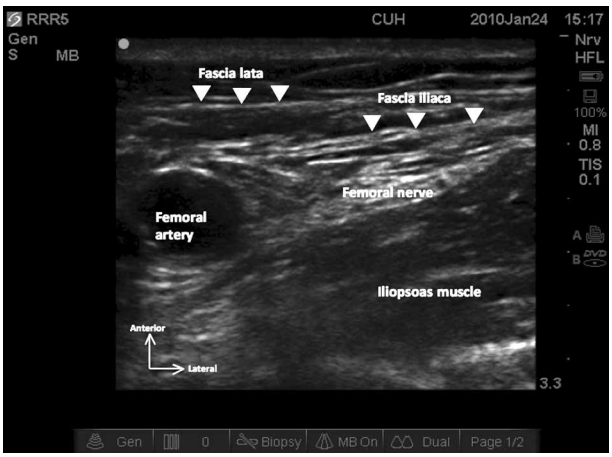

Fig 1. Scout scan of the left femoral nerve (short axis) at the level of inguinal crease (lateral to femoral artery, deep to fascia lata, superficial to iliopsoas muscle)

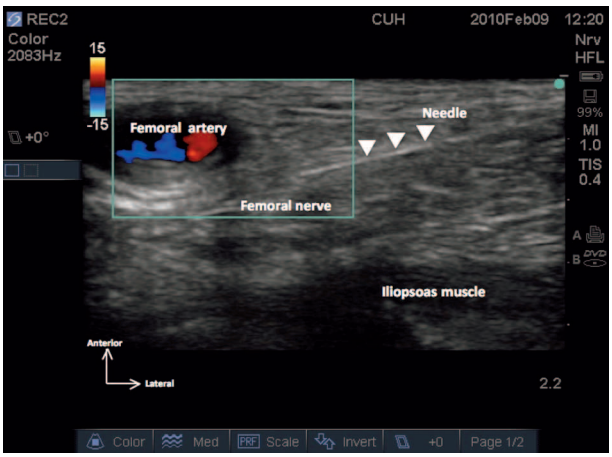

Fig 2. Doppler identification of intravascular flow; needle in plane

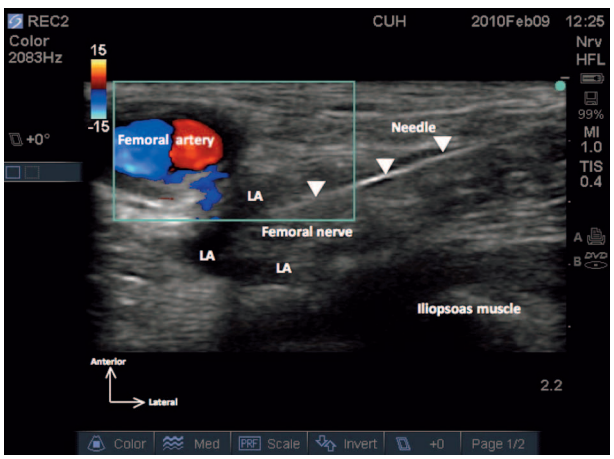

Fig 3. Circumferential spread of local anaesthetic solution following injection between femoral artery and nerve (aggressive appoach). Doppler used to avoid intravascular injection

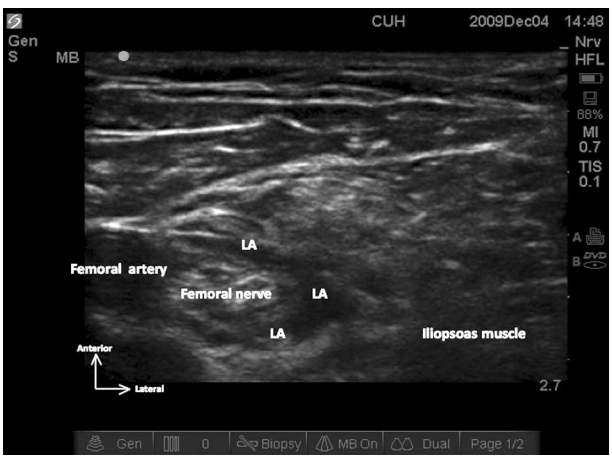

Fig 4. Femoral nerve surrounded by local anaesthetic solution following needle withdrawal. LA local anaesthetic solution

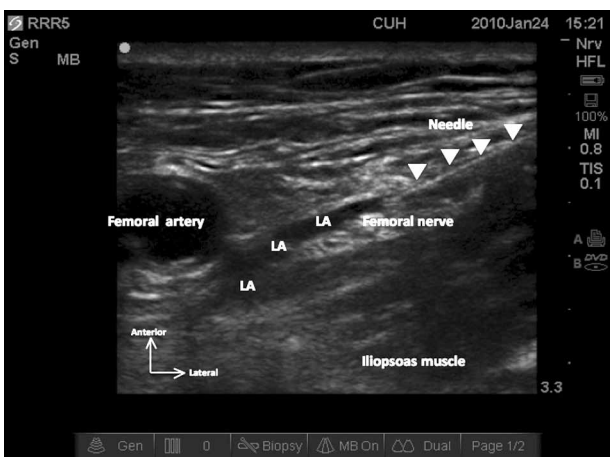

Fig 5. Left femoral nerve (short axis) more visible following injection of some local anaesthetic solution around it. The needle is approaching in plane. LA local anaesthetic solution

neural target and its surrounding structures, assessment of adequate needle-tip position, observation of local anaesthetic spread around the target nerve, identification of anomalous anatomy or pathology. Ultrasound guidance holds the potential to minimize complications associated with peripheral nerve blockade such as nerve injury or inadvertent intravascular injection of local anaesthetics. However, no clinical studies exist to confirm or refute these potential advantages of ultrasound guidance, and both nerve injury and intravascular injection has occurred despite its use. In addition the technique is highly operator dependent [8].

Visualization of nerves with ultrasound depends on the operator's ability to properly locate the nerve, handle the transducer, maximize the ultrasound machine capability (e.g., the choice of transducer frequency, proper adjustment of depth, focus and gain and the use of com-

pound imaging). Needling requires considerable hand-eye coordination [9].

Single shot

Out of plane needle insertion technique

A 5 cm 22 G insulated needle (preferably with an echogenic tip design) is inserted perpendicular to the transducer and the ultrasound beam (fig 6a). In this case, only the cross section of the needle shaft (a white dot) may be observed during needle advancement. It can be technically challenging to track the location of the needle tip during out of plane needle insertion. Gentle scanning over the needle may prove useful. Injection of a small amount of fluid e.g., glucose 5% or local anaestehtic (hydrolocalization) may expand the femoral triangle and the hypoechoic fluid collection can bring the hyperechoic nerve and the fascia iliaca into view [7]. Correct needle tip location may be confirmed by electrical stimulation aiming for patellar movement.

In plane needle insertion technique

The in plane approach is most commonly used for femoral nerve block by aligning the block needle with the ultrasound beam (fig 2, 3, 5, 7). The needle shaft and tip can be visualized distinctly but it may take a longer time to align the needle with the beam compared to the out of plane approach. Also, depending on the depth of femoral nerve, a longer needle may be required.

Fascia iliaca block

In essence this is an indirect femoral nerve block (fig 7). Traditionally, a blunt needle has been used to perform a 'two pop' technique at the junction of lateral one third and medial two thirds of the inguinal ligament. Whit ultrasound, whether using and in plane or out of plane approach at couple of centimeters laterally from the neurovascular bundle, the aim is to pierce both fascia lata and fascia iliaca and observe the spread of local anaesthetic solution medially towards the femoral nerve. Higher volumes of local anaesthetic solution may be necessary [5].

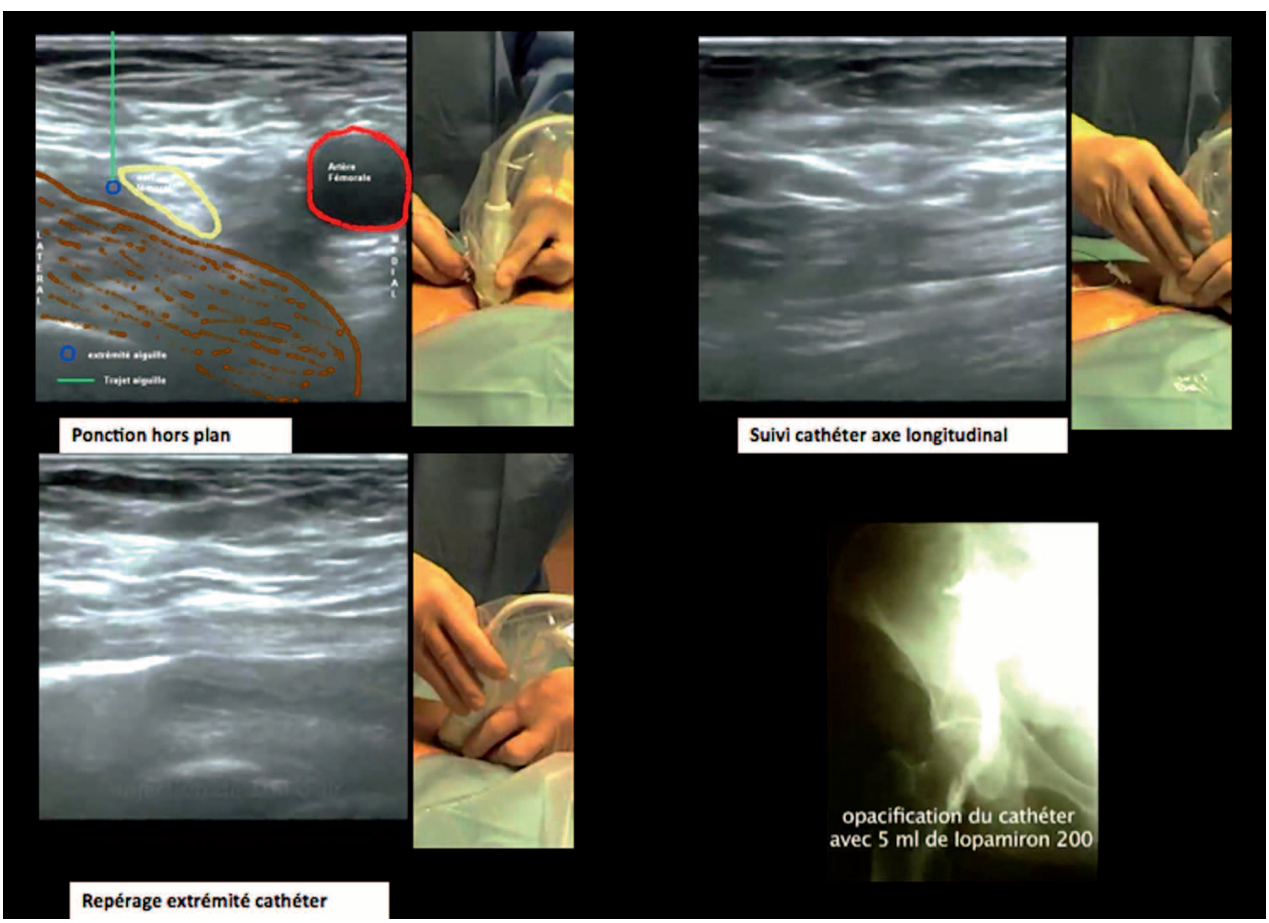

Fig 6. Sequence of catheter insertion; a) top left: out of plane puncture adjacent to femoral nerve; b) top right: probe turned to visualize nerve in long axis, catheter inserted through needle appears alongside the nerve; c) bottom left: catheter tip confirmed by injecting 1 mL of air; d) bottom right: correct position of catheter confirmed with opacification

Catheter technique

Duration of analgesia may be extended beyond the pharmacologic effect of a single shot injection using perineural indwelling catheters through which local anaesthetic solution may be administered up to 72 hours [10]. Regimens include repeted boli, continuous infusions or patient controlled boli with or without a background infusion of local anaesthetic solutions. Risk of infection may be minimized by strictly adhering to sterility guidelines (mask, sterile gown, gloves, ultrasound probe sheat and gel, antiseptic solution, etc).

Several technical issues are specific to continuous perineural catheter placement [11, 12]. The optimal method is still unknown. Herein we illustrate the technique most often used at our institution (fig 6) whereby the nerve (in short axis) is approached through an out of plane needle insertion using a catheter trough needle technique (fig 6a). Local anaesthetic solution may be injected at this point to dilate the perineural space. This will facilitate further visualization of the nerve and the actual catheter insertion and advancement. The next manouvre is to turn the ultrasound probe aiming to visualize both the nerve in long axis and the needle in plane (fig 6b, c, 8). In this view the catheter may be visualized appearing through the needle tip and positioning itself alongside the nerve (fig 9). A small volume of air may be injected to confirm the location of the catheter tip (fig 10). The ultimate confirmation, although not performed routinely, is opacification of the catheter (fig 6d). Alternatively, the catheteter may be inserted blindly through the neeedle and its position subsequently confirmed using ultrasound as described (fig 11, 12).

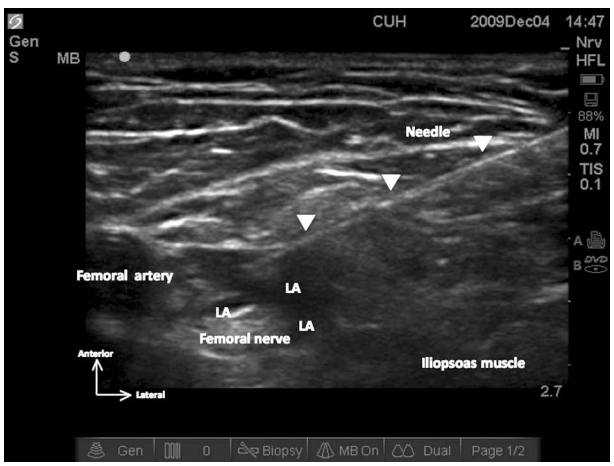

Fig 7. Needle in plane, femoral nerve in short axis, local anaesthetic being deposited around it (needle tip at distance from nerve, conservative approach). LA local anaesthetic solution

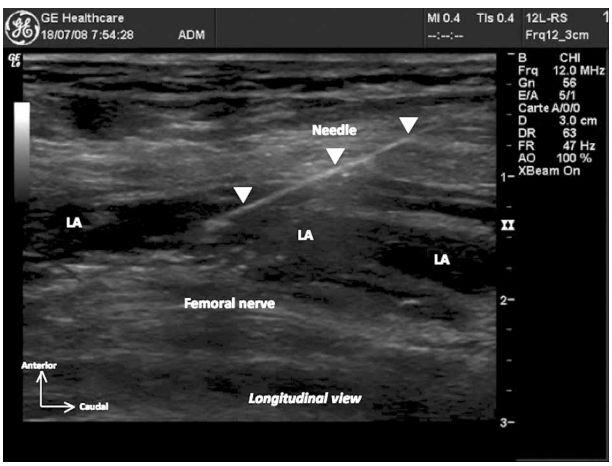

Fig 8. Needle approaching in plane, femoral nerve visualised in long axis. LA local anaesthetic solution

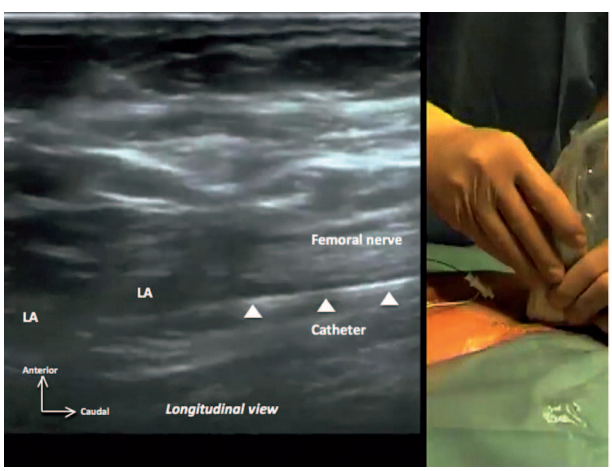

Fig 9. The echogenic catheter parallel to femoral nerve in longitudinal view

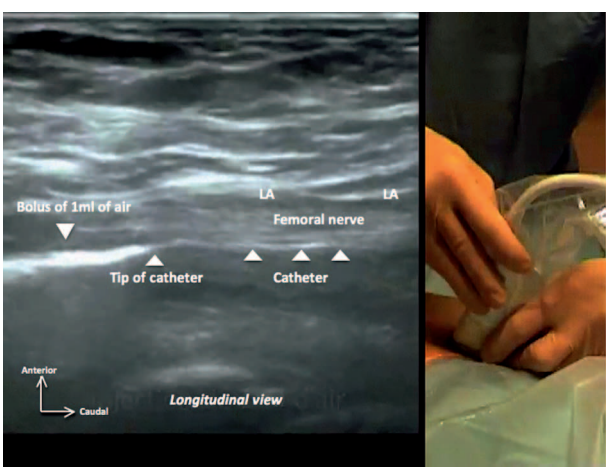

Fig 10. Correct position of catheter tip verified with injection of an air bubble

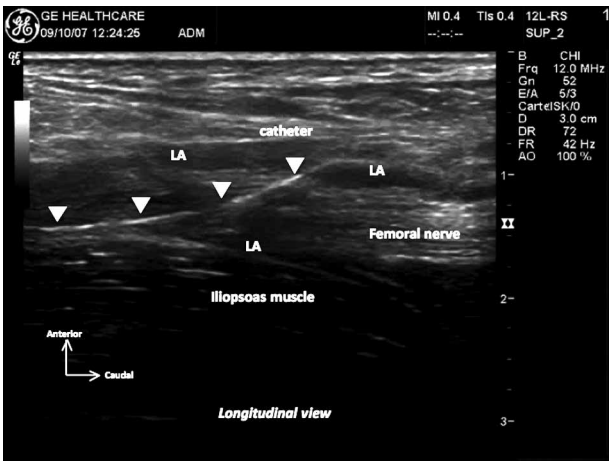

Fig 11. Catheter crossing the femoral nerve and disappearing in the pelvis alongside the nerve. LA local anaesthetic solution

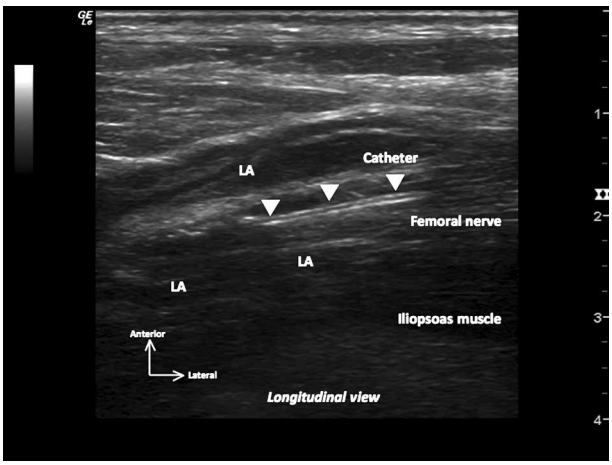

Fig 12. Catheter adjacent to femoral nerve in long axis surrounded by local anaesthetic solution (LA)

Future directions

Currently, research is ongoing with regards to minimal efficient local anaesthetic dose and volume, with regards to the effect of different distribution patterns of local aanesthetic around nerves, finding the best delivery, dosing strategy and drug combinations for perineural infusions to mention but a few. Similarly, the ideal local anaesthetic is still awaited, to provide prolonged selective sensory blockade with no motor block.

In conclusion, a simple technique is described to perform a femoral nerve block using ultrasound guidance. With increasingly available ultrasound machines it is concievable that this technique will become standard practice in the near future. However, adherence to standard monitoring, asepsis, prevention of complications and immediate availability of emergency drugs should not be underestimated.

References

1. Barthelet Y, Morau. [Use of locoregional anesthesia in prehospital medicine] Ann Fr Anesth Reanim 1999; 18: 280-281.
2. Biboulet P, Morau D, Aubas P, Bringuier-Branchereau S, Capdevila X. Postoperative analgesia after total-hip arthroplasty: Comparison of intravenous patient-controlled analgesia with morphine and single injection of femoral nerve or psoas compartment block. a prospective, randomized, double-blind study. Reg Anesth Pain Med 2004; 29: 102-109.
3. Barrett J, Harmon D, Loughnane F, Finucane B, Shorten G. Peripheral nerve blocks and peri-operative pain relief. 1st ed. Philadelphia, PA: W.B. Saunders Company; 2004.
4. Kamina P. Precis d'anatomie clinique. Tome 1. Paris: Maloine, 2003.
5. Capdevila X, Biboulet P, Bouregba M, Barthelet Y, Rubenovitch J, d'Athis F. Comparison of the three-in-one and fascia iliaca compartment blocks in adults: clinical and radiographic analysis. Anesth Analg 1998; 86: 1039-44.
6. Capdevila X, Biboulet P, Morau D, Mannion S, Choquet O. How and why to use ultrasound for regional blockade. Acta Anaesthesiol Belg 2008; 59: 147-154.
7. O'Donnell B, Mannion S. Ultrasound-guided femoral block, the safest way to proceed? Reg Anesth Pain Med 2006; 31: 387-383.
8. Sites BD, Chan VW, Neal JM, Weller R, Grau T, Koscielniak-Nielsen ZJ, Ivani G.The american society of regional anesthesia and pain medicine and the European society of regional anaesthesia and pain therapy joint committee recommendations for education and training in ultrasound-guided regional anesthesia. Reg Anesth Pain Med 2010; 35: S74-80.
9. Neal JM, Brull R, Chan VW, Grant SA, Horn JL, Liu SS, McCartney CJ, Narouze SN, Perlas A, Salinas FV, Sites BD, Tsui BC. The ASRA evidence-based medicine assessment of ultrasound-guided regional anesthesia and pain medicine: Executive summary. Reg Anesth Pain Med 2010; 35: S1-9.
10. Morau D, Lopez S, Biboulet P, Bernard N, Amar J, Capdevila X. Comparison of continuous 3-in-1 and fascia Iliaca compartment blocks for postoperative analgesia: feasibility, catheter migration, distribution of sensory block, and analgesic efficacy. Reg Anesth Pain Med 2003; 28: 309-314.
11. Wang AZ, Gu L, Zhou QH, Ni WZ, Jiang W. Ultrasound-guided continuous femoral nerve block for analgesia after total knee arthroplasty: catheter perpendicular to the nerve versus catheter parallel to the nerve. Reg Anesth Pain Med 2010; 35: 127-131.
12. Kadic L, Boonstra MC, DE Waal Malefijt MC, Lako SJ, VAN Egmond J, Driessen JJ. Continuous femoral nerve block after total knee arthroplasty? Acta Anaesthesiol Scand 2009; 53: 914-920.